

A Reduced Grade of Liver Fibro-steatosis after Raltegravir, Maraviroc and Fosamprenavir in an HIV/HCV Co-infected Patient with Chronic Hepatitis, Cardiomyopathy, Intolerance to Nelfinavir and a Marked Increase of Serum Creatine Phosphokinase Levels Probably Related to Integrase Inhibitor Use

A Degli Antoni¹, LE Weimer², R Manfredi³, V Fragola², C Ferrari¹

ABSTRACT

The use of new antiretroviral drugs in HIV infection is particularly important in patients with intolerance or resistance to other antiretroviral agents. Raltegravir and maraviroc represent new, important resources in salvage regimens. A reduced grade of liver fibro-steatosis after a combination of raltegravir and maraviroc (second-line) has not been studied and the mechanism by which these new drug classes induced a marked reduction of grade of liver diseases is currently unknown. In the present case report, nested in an ongoing multicentre observational study on the use of new antiretroviral inhibitors in heavy treatment-experienced HIV patients, we evaluated the correlation between a "short therapeutic regimen" raltegravir, maraviroc and fosamprenavir and liver diseases. The aim of this report is to describe the use of a three-drug regimen based on two novel-class antiretroviral agents (raltegravir and maraviroc) plus the protease inhibitor fosamprenavir, in an experienced HIV-infected patient with chronic progressive hepatitis C complicated by liver fibrosis; an overwhelming increased serum creatine kinase level occurred during treatment, and is probably related to integrase inhibitor administration. At present no information is available regarding this correlation.

Keywords: Antiretroviral treatment, chronic active hepatitis, fosamprenavir, HIV/HCV, maraviroc, raltegravir

Grado Reducido de Fibroesteatosis tras la Administración de Raltegravir, Maraviroc y Fosamprenavir en un Paciente Co-infectado de VIH/VHC con Hepatitis Crónica, Cardiomiopatía, Intolerancia al Nelfinavir y un Aumento Pronunciado de los Niveles de Creatina Fosfoquinasa Sérica Probablemente Debido al Uso del Inhibidor de la Integrasa

A Degli Antoni¹, LE Weimer², R Manfredi³, V Fragola², C Ferrari¹

RESUMEN

El uso de nuevos medicamentos antiretrovirales para la infección por VIH es particularmente importante en los pacientes con intolerancia o resistencia a otros agentes antiretrovirales. Raltegravir (RTV) y maraviroc (MRV) representan nuevos e importantes recursos en las terapias de salvamento. Un grado reducido de fibroesteatosis hepática después de una combinación de raltegravir y maraviroc (terapia de segunda línea) no ha sido estudiado, y el mecanismo por el cual estas nuevas clases de droga indujeron una marcada reducción de grado de las enfermedades hepáticas se desconoce hasta el momento.

Como parte de la realización en curso de un estudio observacional multicentro acerca del uso de nuevos inhibidores antiretrovirales en pacientes de VIH altamente experimentados en el tratamiento, en

From: ¹Department of Immunology, University of Parma, Italy, ²Department of Therapeutic Research and Medicines Evaluation, Istituto Superiore di Sanità, Rome, Italy and ³Department of Infectious Diseases, Hospital Sant'Orsola, Bologna, Italy.

Correspondence: Dr LE Weimer, Istituto Superiore di Sanità, Department of Therapeutic Research and Medicines Evaluation, Rome, Italy. E-mail: liliana.weimer@iss.it

el presente reporte de caso se evalúa la correlación entre un “régimen terapéutico corto” (raltegravir, maraviroc y fosamprenavir) y las enfermedades del hígado.

El objetivo de este reporte es describir el uso de un régimen de tres medicamentos – basado en dos agentes antiretrovirales de nuevo tipo (raltegravir y maraviroc) además del fosamprenavir inhibidor de la proteasa – en un paciente de VIH experimentado. El paciente también sufre de hepatitis C evolutiva, progresiva, crónica, complicada por fibrosis hepática. Durante el tratamiento, se produjo un aumento extraordinario del nivel de creatina quinasa sérica, el cual probablemente esta relacionado con la administración del inhibidor de la integrasa. Actualmente no hay información disponible con respecto a esta correlación.

Palabras claves: Tratamiento antiretroviral, hepatitis activa crónica, fosamprenavir, VIH/VHC, maraviroc, raltegravir

West Indian Med J 2012; 61 (9): 933

INTRODUCTION

In July 2009, the US Food and Drug Administration (FDA) approved raltegravir, the HIV integrase inhibitor to be used as salvage and also first- and early-line treatment for adults infected with HIV-1 (1). In a dramatically short period of time, this drug belonging to the novel class of integrase inhibitors has demonstrated unprecedented reductions in plasma HIV-RNA levels, and extremely significant and rapid increase of peripheral CD4⁺ T-lymphocyte counts (2).

Co-infection with hepatitis viruses and chronic liver diseases is well known as a common clinical problem in patients infected with HIV-1, mainly due to the route of transmission, shared by all quoted viruses. Currently, the combination of two new antiretroviral classes that includes an HIV protease inhibitor without booster is an attractive option.

In the field of management of antiretroviral-experienced HIV-infected patients with chronic hepatitis C virus (HCV) and co-existing limited active therapeutic options of salvage regimens, a switch to a simplified regimen to second- or further-line of treatment may represent an ideal choice for highly experienced HIV-infected patients who suffered from previous therapeutic failures and/or intolerance, and/or low adherence levels to prescribed medications.

The aim of this report is to describe the use of a three-drug regimen based on two novel-class antiretroviral agents (raltegravir and maraviroc) plus the protease inhibitor fosamprenavir in an experienced HIV-infected patient with chronic progressive hepatitis C complicated by liver fibrosis. A very high serum creatine kinase level occurred during treatment, and is probably related to integrase inhibitor administration.

CASE REPORT

A male Italian subject aged 44 years, with a history of drug and alcohol abuse since 1983, with a CD4⁺ T-lymphocyte count of 328 cells/mm³ and plasma HIV-RNA viraemia of 3.79 Log₁₀ copies/mL, was started in December 2008 on raltegravir (at 400 mg twice daily), maraviroc (300 mg twice daily), and fosamprenavir (700 mg twice daily); at that time, the patient was clinically asymptomatic.

HIV-1 infection had been diagnosed in the year 1985, following a hospital admission due to a severe (grade 3) cutaneous rash, whose cause was not identified. Based on his satisfactory virological and immunological condition, no antiretroviral treatment was administered over 16 years (from 1985 until 2001).

A chronic HCV co-infection (due to a genotype 1a virus) was diagnosed in December 2001 by routine serological screening. At that time, a significant worsening of laboratory parameters of HIV disease (CD4⁺ T-cell count dropped to 66 cells/μL, and plasma HIV-RNA was 5127 Log₁₀ copies/mL) prompted combination antiretroviral therapy (cART) which included zidovudine, lamivudine and nelfinavir. Subsequently, the patient experienced numerous changes to his cART regimen, due to poor compliance and insufficient virological-immunological results. Among others, in September 2003, nelfinavir was replaced with abacavir, zidovudine and lamivudine due to intolerance; in October 2003, abacavir was substituted with didanosine, zidovudine and lamivudine because of a severe (grade 3) cutaneous rash.

In November 2004, based on an HIV genotype resistance testing, the cART was changed, leading to the introduction of zidovudine, lamivudine and lopinavir/ritonavir (the option of efavirenz therapy was refused).

In August 2007, the patient was diagnosed with focal seizures, so he was started on sodium valproate (from August 2007 until September 2008) together with his cART, in order to prevent further episodes or chronic epilepsy (probably related to drug use).

Subsequent laboratory controls performed in January 2008 showed a low virological immunological response of the underlying HIV disease (as demonstrated by a CD4⁺ count of 352 cells/μL (21% of overall T-lymphocytes), and a plasma HIV-RNA of 1.78 Log₁₀ copies/mL. As a result, the lopinavir/ritonavir-containing cART was replaced by another cART regimen based on emtricitabine, tenofovir and atazanavir which would provide lower cardiovascular risk; a genotypic testing was not available.

With regard to the co-existing chronic hepatitis C, an abdominal ultrasonography examination showed signs of

severe, extensive liver fibrosis, and identified a reduction of the size of the right lobe of the liver, with relative enlargement of the left one. A liver biopsy and histopathological examination confirmed severe HCV disease progression, as expressed by a grade 3 fibrosis, together with necrosis of hepatocytes and focal inflammatory foci in the liver parenchyma and the portal areas, further complicated by multiple bridging fibrosis which linked up portal and central areas of the examined liver tissue.

In January 2008, the patient was hospitalized due to an episode of syncope. Clinical and echocardiographic studies detected a previously missed, dilated cardiomyopathy, whose pathogenesis was attributed to HIV infection itself, since other risk factors were lacking. As a consequence, a new cART was considered: tenofovir, emtricitabine, and atazanavir (which represented a novel HIV protease inhibitor with lower metabolic risk), administered at 200 mg twice daily, without ritonavir booster. The cardiovascular risk profile of the patient was related to cigarette smoking, and also high blood pressure, dyslipidaemia and the metabolic syndrome.

A few months later, routine laboratory controls showed a significant rise of the CD4⁺ T-cell count (up to 328 cells/mm³ (21% of total T-lymphocytes), and a lowering of plasma HIV-RNA levels (3.71 Log₁₀ copies/mL).

In December 2008, a new, attractive cART regimen based on raltegravir, maraviroc and fosamprenavir was started. The introduction of the integrase inhibitor raltegravir was motivated by a viral load rebound (number of HIV-RNA copies/mL 61461 if a resistance testing was not available), by continued compliance problems, and especially by the concurrent, severe cardiovascular and liver diseases already diagnosed, which prompted the use of drugs with a more friendly toxicity-tolerability profile, joined with a maintained, elevated activity on a highly resistant HIV. Maraviroc represented the major companion drug of this salvage cART regimen, due to the limited, residual therapeutic options based on genotype test, and a maintained CCR5 tropism at the “Trofile” testing.

In January 2009 (only one month after the last treatment switch), the patient showed a very effective and sustained virological and immunological response of his HIV disease (as assessed by a rise of the CD4⁺ count to 425 cells/mm³ and a reduction of HIV-RNA levels to 1.69 Log₁₀ copies/mL).

A few weeks later, he had further routine controls, with biochemical studies showing increased serum creatine phosphokinase level (461 U/L) probably related to raltegravir administration, since at the time of therapeutic switch a normal value (161 U/L) was observed, and a subsequent laboratory control showed a moderate increase (224 U/L).

Neither clinical signs of rhabdomyolysis (*ie* fatigue, skeletal muscle pain), nor laboratory signs of metabolic dysfunction (*ie* lactic acidosis, increased serum aldolase and myoglobin levels, kidney impairment, and electrolyte

abnormalities) were observed throughout the subsequent follow-up (from January 2009 to February 2010).

During the subsequent three months of clinical examinations, the patient maintained stable, good clinical condition, and an adequate adherence to therapy. In May 2009, the CD4⁺ T-lymphocyte count increased to 421 cells/mm³, while plasma HIV-RNA levels decreased, but remained detectable (1.6 Log₁₀ copies/mL).

Surprisingly, no remarkable clinical and laboratory signs of toxicity and progression of the concurrent HCV liver disease occurred, as demonstrated by repeated ultrasonographic, biochemical and haematological examinations (Figs. 1, 2). Moreover, a repeated liver biopsy examination showed

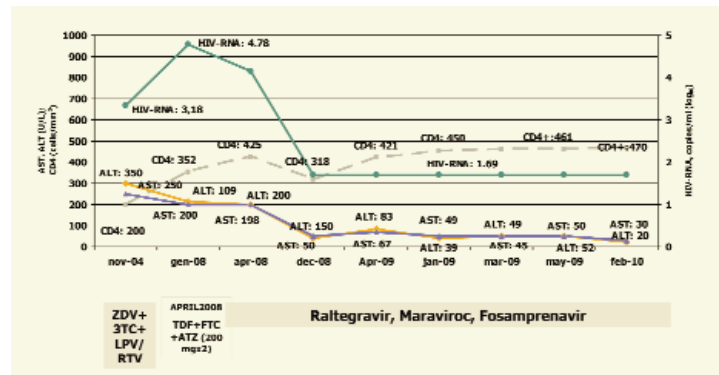


Fig. 1: Temporal assessment of HIV-RNA viral load, CD4 T-lymphocyte count and relationship with antiretroviral treatment, as observed in the patient.

ZDV: zidovudine; 3TC: lamivudine; LPV/r: lopinavir/ritonavir; TDF: tenofovir; FTC: emtricitabine; ATZ: atazanavir.

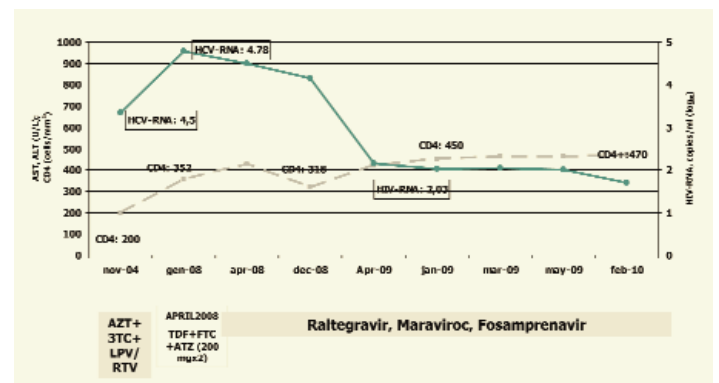


Fig. 2: Temporal assessment of HIV/HCV RNA viral load and relationship with antiretroviral treatment, as observed in the patient.

ZDV: zidovudine; 3TC: lamivudine; LPV/r: lopinavir/ritonavir; TDF: tenofovir; FTC: emtricitabine; ATZ: atazanavir

a reduced grade of histopathological fibrosis, extending out from the portal areas with only rare “bridges” between central and portal areas of the liver (grade 2 fibrosis, compared with a previous grade 3 fibrosis). Both abdominal ultrasonography and liver histopathology were assessed and compared by the same staff physicians.

DISCUSSION

In this case report, the administration of a cART regimen including raltegravir and maraviroc, together with unboosted fosamprenavir, as a salvage regimen in a patient with HIV and HCV co-infection, prior drug and alcohol abuse, a dilated cardiomyopathy, and a documented severe progressive chronic HCV hepatitis complicated by advanced fibrosis, is presented. In particular, raltegravir and maraviroc have been selected as members of novel anti-HIV classes in a patient with limited therapeutic options due to an extensive resistance profile, and prior tolerability and adherence concerns. A protease inhibitor like fosamprenavir was used without ritonavir booster, in order to reduce the potential cardiovascular risk, and to exploit the favourable tolerability profile of this last drug in patients with either cardiovascular and/or liver abnormalities, as well as to encourage the initial lack of therapeutic compliance demonstrated by the patient.

During his cumbersome clinical history, the patient experienced numerous antiretroviral regimens without obtaining an effective and sustained virological and immunological response, so that the choice of the introduction of a "short and light" regimen containing a protease inhibitor without ritonavir booster seems an attractive therapeutic and simplified option for subjects like ours.

This case report raises the question of whether the concurrence of HIV disease and chronic hepatitis due to HCV infection may contribute to the development of severe hepatopathy, or may be responsible for a more severe or more rapid liver damage. In our case, initial examination showed that the underlying HCV hepatopathy was particularly severe, thus confirming that HIV-HCV co-infection may narrow cART therapeutic options, especially during second-line and even more where salvage therapy is of concern. Although considering the intrinsic limitations due to our anecdotal observation, raltegravir plus maraviroc, in association with a HIV protease inhibitor without ritonavir booster, may be an attractive option to treat antiretroviral-experienced HIV-infected patients with concurrent, severe chronic hepatitis C, limited active therapeutic options of salvage regimen, need to maintain stable biochemical, haematological and clinical conditions (due to other comorbidities like cardiomyopathy and creatine kinase elevation in our case), and prior, unsatisfactory adherence to multiple attempted cART regimens. The achieved, documented reduced progression of the already diagnosed severe liver disease (hepatic fibrosis grade 3, as assessed since 2007), needs further interpretation, on the grounds of the limited hepatic toxicity of the employed anti-HIV drugs, as well as the potential effectiveness of maraviroc against HCV infection.

Another important issue is represented by the definition of second- and further-line regimens in HIV/HCV co-infected patients showing failure, intolerance to protease

inhibitors, and limited antiretroviral effective options. In patients who develop protease inhibitor intolerance or resistance, and also suffer from chronic active hepatitis, reduced options are still available for the design of second- and further-line cART regimens, and the recently introduced integrase inhibitors [like raltegravir] (3) and co-receptor inhibitors (like maraviroc) represent a recent and promising advance in this scenario (4). In our case, a surprisingly effective, prompt, and safe response was observed (Fig. 1), but it is still uncertain to what extent a durable response may be obtained with these compounds, and which drugs represent the best partners for them in each individualized cART regimen.

The use of raltegravir and/or maraviroc in association with protease inhibitors proved to be effective in patients who had become resistant or intolerant or poorly adherent to other drugs and drug classes (5).

Furthermore, our patient experienced a dramatic increase of his serum creatine phosphokinase levels, associated with moderate signs and symptoms of myopathy, probably attributable to raltegravir (in the absence of other identified risk factors) after eleven months of therapy. Even though no biochemical and ultrasonographic signs of rhabdomyolysis were present, muscle pain, weakness and difficulty in walking, in association with an increase of creatine phosphokinase level up to 2187 U/L, were documented during the course of treatment, but these clinical and laboratory abnormalities proved to be self-limited, and did not lead to drug withdrawal.

In conclusion, this case report indicates that a combination regimen including raltegravir and/or maraviroc plus a well-tolerated, unbooster protease inhibitor could also be explored as a possibly effective alternative in antiretroviral experienced patients with HIV-HCV co-infection progressing toward severe liver disease complicated by extensive fibrosis. Moreover, the underlying, relevant cardiac comorbidity probably attributable to HIV infection itself, the presence of cardiovascular risk factors, and the previous episodes of intolerance and/or poor compliance to single antiretroviral agents or cART regimens make this case of further interest.

Only cohort studies specifically designed for HIV-HCV co-infected patients will be able to confirm the role that cART regimens containing raltegravir and maraviroc may play in reducing the clinical signs and the histopathological progression of chronic HCV liver disease in the HIV co-infected population.

We believe that multicentre clinical studies are needed to define the most effective regimens for HIV-HCV co-infected patients with chronic active hepatitis C and multiple drug resistance and/or intolerance, with the added objective to concurrently reduce the rate of progression of the underlying HCV-related liver disease.

REFERENCES

1. Grinsztejn B, Nguyen BY, Katlama C, Gatell JM, Lazzarin A, Vittecoq D et al. Safety and efficacy of the HIV-1 integrase inhibitor raltegravir (MK-0518) in treatment-experienced patients with multidrug-resistant virus: a phase II randomised controlled trial. *Lancet* 2007; **369**: 1261–69.
2. Markowitz M, Nguyen BY, Gotuzzo E, Mendo F, Ratanasuwana W, Kovacs C et al. Rapid and durable antiretroviral effect of the HIV-1 integrase inhibitor raltegravir as part of combination therapy in treatment-naive patients with HIV-1 infection. Results of a 48-week controlled study. *J Acquir Immune Defic Syndr* 2007; **46**: 125–33.
3. Vispo E, Mena A, Maida I, Blanco F, Cordoba M, Labarga P et al. Hepatic safety profile of raltegravir in HIV-infected patients with chronic hepatitis C. *J Antimicrob Chemother* 2010; **65**: 543–7.
4. Fätkenheuer G, Nelson M, Lazzarin A, Konourina I, Hoepelman AI, Lampiris H et al. Subgroup analyses of maraviroc in previously treated R5 HIV-1 infection. *New Eng Med J* 2008; **359**: 1442–55.
5. Steigbigel RT, Cooper DA, Kumar PN, Eron JE, Schechter M, Markowitz M et al. Raltegravir with optimized background therapy for resistant HIV-1 infection. *New Eng Med J* 2008; **359**: 339–54.