

Evaluation of Common Operator Errors in Panoramic Radiography in Trinidad and Tobago: A Comparison of Formally vs Informally Trained Operators

AK Bissoon¹, E Whaites², K Moze¹, R Naidu¹

ABSTRACT

Aim: To evaluate and compare the frequency of common operator errors seen on panoramic radiographs in dental private practices and in the dental hospital (taken by informally and formally trained operators, respectively) in Trinidad and Tobago.

Method: One thousand panoramic radiographs of patients over the age of 10 years were included in this study. These comprised 500 from the dental hospital and 500 from dental private practices. The radiographs were reviewed using standardized criteria to identify the most common operator errors.

Results: There were only 21 (4.2%) error free radiographs in the dental private practice sample and 29 (5.8%) in the dental hospital sample. Frequencies of specific errors were significantly higher in the dental private practice sample in each category except for "Chin tipped too low" (Chi-square $p < 0.05$)

Conclusion: This study supports the need for the introduction of statutory guidelines with respect to the use of ionizing radiation in dentistry in Trinidad and Tobago and in particular, the implementation of formally assessed dedicated dental radiography training for all operators of dental X-ray equipment.

Keywords: Errors, operator training, panoramic radiography

La Evaluación de los Errores Comunes de los Operadores de Radiografía Panorámica en Trinidad y Tobago Comparación de los Operadores Adiestrados Formalmente Frente a los Adiestrados Informalmente

AK Bissoon¹, E Whaites², K Moze¹, R Naidu¹

RESUMEN

Objetivo: Evaluar y comparar la frecuencia de los errores comunes de los operadores, observados en las radiografías panorámicas en las clínicas dentales privadas y en el hospital de odontología (tomadas por operadores adiestrados formalmente e informalmente, de forma respectiva) en Trinidad y Tobago.

Método: Mil radiografías panorámicas de pacientes de más de 10 años de edad, fueron incluidas en este estudio. Las mismas comprendían 500 provenientes del hospital odontológico y 500 provenían de las prácticas privadas de dentistas. Las radiografías fueron examinadas a partir de criterios estandarizados, a fin de identificar los errores más comunes de los operadores.

Resultados: Hubo sólo 21 (4.2%) radiografías sin errores en la muestra de la clínica dental privada, y 29 (5.8%) en la muestra del hospital de odontología. Las frecuencias de errores específicos fueron significativamente más altas en la muestra de la clínica dental privada en cada categoría, salvo el caso del "mentón inclinado excesivamente hacia abajo" (Chi-cuadrado $p < 0.05$)

Conclusión: Este estudio subraya la necesidad de introducir pautas reglamentarias con respecto al uso de la radiación ionizante en la cirugía dental en Trinidad y Tobago, particularmente en lo que concierne al adiestramiento especializado en radiografía dental, formalmente evaluado, para todos los operadores de equipos de rayos x para el trabajo dental.

From: ¹School of Dentistry, The University of the West Indies, St Augustine, Trinidad and Tobago and ²King's College London Dental Institute, London, United Kingdom.

Correspondence: Dr AK Bissoon, School of Dentistry, The University of the West Indies, St Augustine, Trinidad and Tobago. E-mail: ktlou556@hotmail.com

Palabras claves: Errores, operador adiestrado, radiografía panorámica

West Indian Med J 2012; 61 (7): 734

INTRODUCTION

Dental panoramic radiography is a technique used to produce images of both jaws, their respective dentitions, and supporting structures on a single film. Dental panoramic units produce a curved 'in focus' tomographic image that includes the upper and lower teeth and jaws. This tomographic focal layer or plane is produced by rotating the tube head and image receptor carriage around the head of the patient during the exposure. The equipment employs a slit-collimated vertical X-ray beam, with an eight degree-upward inclination. The patient needs to be positioned so that their teeth are situ-

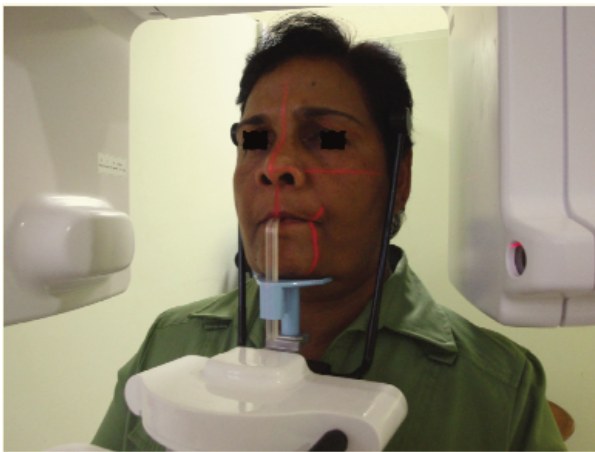

Fig. 1: Patient positioned in panoramic machine with three light positioning markers.

ated within the equipment's focal trough. This is achieved typically by using a bite-peg, three light positioning markers (Fig. 1) and by following the manufacturer's instructions precisely (1).

Panoramic radiography is a difficult radiographic technique to perfect and panoramic radiographs are known to be difficult to expose without errors (2). The preparation of the patient and positioning of the patient's head within the panoramic equipment is crucial to the diagnostic quality of the image. Common technical and patient positioning errors as well as artifacts can lead to inadequate diagnostic quality (3–5). Several studies have been published on the frequency and rate of errors seen on panoramic radiographs (5–9). According to Kaviani *et al* (9), some of the most common errors (78%) observed on panoramic radiographs were related to patient positioning. Mckee *et al* (10) also reported that the "positioning of patient" error was most common (89.3%). Research reports show a variation in the most common patient positioning errors, some reporting the most common positioning error to be failure to place the tongue against the palate (10–11) and another (9), reporting rotation of the head as the most common error.

The aim of this study was to evaluate and compare the frequency of common operator patient preparation and positioning errors seen on panoramic radiographs in dental private practices and in the dental hospital (taken by informally and formally trained operators, respectively) in Trinidad and Tobago.

SUBJECTS AND METHOD

Approval was granted by the Dental Council of Trinidad and Tobago and the Medical Chief of Staff of the Eric Williams Medical Sciences Complex. The subjects were patients greater than 10 years old attending the dental hospital and dental private practices. Edentulous subjects were excluded. A total of 1000 radiographs were assessed. These comprised 500 dental panoramic radiographs from the dental hospital taken by formally trained operators and 500 from dental private practices taken by informally trained operators. Twenty out of 24 dental private practices that own and operate dental panoramic machines in Trinidad and Tobago consented to participate. Dental private practices with formally trained operators were excluded.

Twenty-five suitable dental panoramic radiographs were obtained from patient records at each of the 20 participating practices. Five hundred suitable patient records held in the dental hospital were requested from the Medical Records Department. The radiographs were photographed using a Sony Cyber shot 10.1 megapixel digital camera (model DSC-W170) and imported to a Gateway laptop computer. Each radiograph was assessed for the errors summarized in Table 1. Each positioning error and its resultant

Table 1: Summary of errors assessed on each panoramic radiograph

Patient preparation errors	Patient positioning errors
Presence of radiopaque artifacts (earrings, necklace, prostheses, lead apron, spectacles <i>etc</i>)	Patient too far forward
	Patient too far backward
	Chin tipped too low
	Chin tipped too high
	Asymmetrical placement of teeth in focal trough due to rotation of the head
	Superimposition of air shadow above tongue on apices of maxillary teeth due to patient not raising tongue against palate
	Patient slumped causing extreme lightness in anterior region as a result of superimposed spine shadow

identifying features on the panoramic radiograph were assessed using Table 2 (12).

Table 2: Positioning errors and the resultant identifying features on the panoramic radiograph

Error and cause	Identifying features
Patient too far forward	Narrow blurred anterior teeth with pseudo space Superimposition of spine on ramus Bicuspid overlap bilaterally
Patient too far back	Wide, blurred anterior teeth Ghosting of rami; spread-out turbinates, ears, and nose in image, condyles off lateral edges of film
Chin tipped too low	Excessive curving of occlusal plane Loss of image of the roots of the lower anterior teeth Narrowing of the intercondylar distance and loss of the head of the condyles at the top of the film
Chin raised too high	Flattening or reverse curvature of occlusal plane Loss of image of the roots of the upper anterior teeth Lengthening of the intercondylar distance and loss of the head of the condyles at the edges of the film Hard palate shadow wider and superimposed on apices of maxillary teeth
Head twisted/rotated	Unequal right-left magnification particularly of teeth and ramus Severe overlap of contact points and blurring
Slumped position	Ghost image of cervical spine superimposed on the anterior region
Tongue not on palate	Radiolucency obscuring maxillary apice

To evaluate reliability for assessing patient preparation and positioning errors, 50 radiographs were assessed by the main investigator. The said radiographs were then assessed utilizing the same parameters by another similarly trained dentist. The Kappa statistic was then derived to determine inter-examiner agreement.

Data recording and analysis

Microsoft Office Excel 2007 was used to record the presence or absence of each error on the radiograph. Each radiograph was numbered and the number entered into a column labelled "Sr. No" to denote its serial number. The presence of an error was denoted by the letter "Y" and the absence by the letter "N" in the corresponding row to the serial number of the radiograph.

In order to quantify the presence and absence of errors denoted by Y and N, respectively, an "If... Then.... Else" statement was developed to convert the "Y" to one and the "N" to zero. This was achieved through the use of Microsoft Office Excel 2007. The ones were then summed to determine the total number of errors in each category.

In order to determine the significance of differences in the frequency of errors between the dental private practice sample and the dental hospital sample, 2 x 2 contingency Chi-square (χ^2) tables were used. The level of statistical significance was $p < 0.05$ otherwise denoted as not significant. Whenever any cell was less than six then Yates' correction for continuity (χ^2_{Yates}) (13), was applied.

RESULTS

Out of the 500 panoramic radiographs viewed in the dental private practice sample, 21 (4.2%) showed no preparation or positioning errors according to the eight criteria.

The most common error observed in this sample was rotation of the head [74%] (Fig. 2), followed by failure to place the tongue on the palate [68.6%] (Fig. 3). The least frequent error observed (8%) was the presence of radiopaque artifacts caused by failure to remove metallic accessories, prostheses and the use of the lead apron during exposure (Figs. 4 and 5).

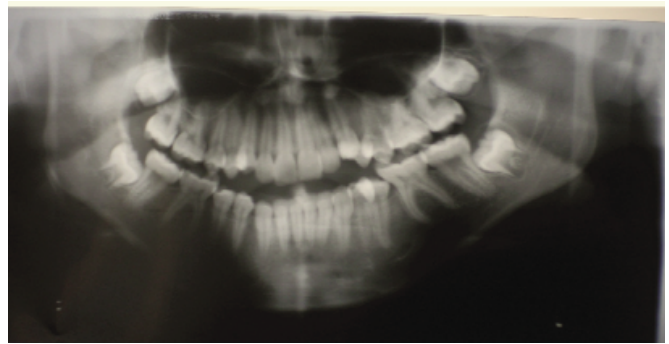


Fig. 2: Patient rotated to the right – unequal right to left magnification of posterior teeth and rami (horizontal positioning error).

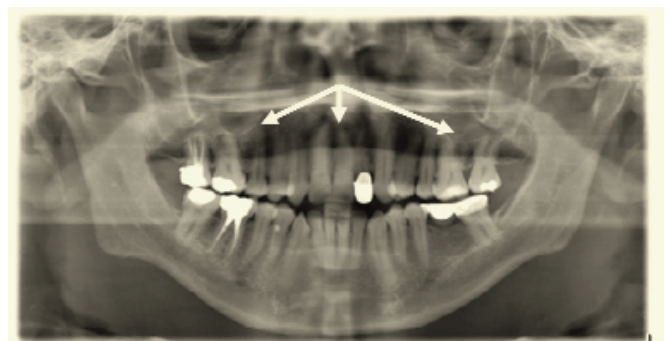


Fig. 3: Failure to place the tongue on the palate during the exposure resulting in superimposition of palatoglossal air shadow on maxillary apices (arrows).

From a total of 500 radiographs viewed in the dental hospital, 29 (5.8%) were found to be error free according to the eight criteria.

Failure to place the tongue on the palate (62%) was the most common error observed in the dental hospital sample. This was followed by rotation of the head (58.8%). The least

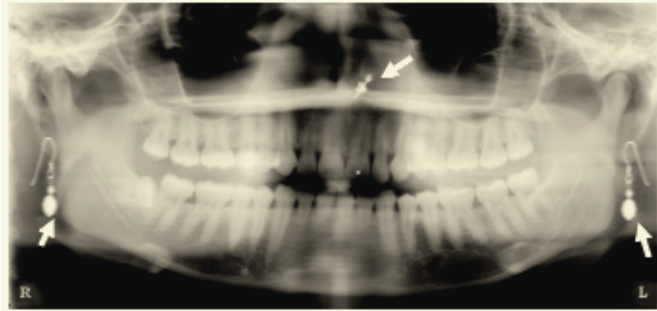


Fig. 4: Failure to remove earrings and nose ring resulting in radiopaque artifacts (arrows).

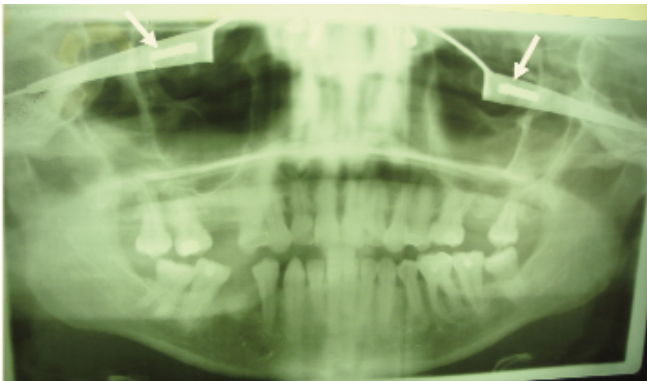


Fig. 5: Failure to remove spectacles resulting in radiopaque artifact (arrows).

frequent error in this sample was the presence of radiopaque artifacts which was seen in six radiographs (1.2%).

The frequency of errors was higher in each category in dental private practice than in the dental hospital except in the “Chin too low” category. Rotation of the head and failure to place the tongue on the palate were the two most common errors in both samples. Figure 6 is a graphical representation of these findings.

There was a statistically significant difference of error frequencies between both samples in each error category ($p < 0.05$) as assessed using 2 x 2 contingency Chi-square (χ^2) tables. In assessing reproducibility, the Kappa statistic was derived to determine inter-examiner agreement. Its value was calculated to be 0.4804. According to Altman (14), the value shows moderate agreement between the two examiners.

DISCUSSION

In order for panoramic radiography to be beneficial as a diagnostic tool, the overall quality must be in accordance with quality targets. These quality targets can be benchmarked against those in the United Kingdom’s (UK) 2001 “Guidance Notes for Dental Practitioners on the Safe Use of X-ray Equipment” (15), which recommends that not less than 70% of images should be graded “1” or “excellent” and show no errors of exposure, positioning or processing. Poor quality

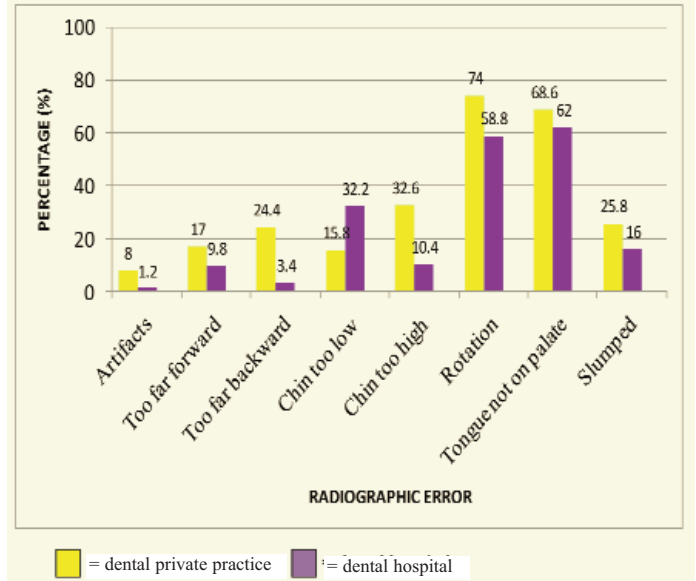


Fig. 6: Comparison of frequency distribution of errors on panoramic radiographs in dental private practice with the dental hospital.

generally results in the need to retake images which has several consequences, the most serious of which is additional radiation dose to the patient. Given the 2007 recommendations of the International Commission on Radiological Protection (ICRP) which result in an upward reassessment of fatal cancer risk from oral and maxillofacial radiographic examinations (16), it is important that retakes be kept at a minimum. Other consequences are increased cost and extended examination times. The effect of additional cost significantly increases the financial burden of patients in Trinidad and Tobago since they are responsible for payment in full when they do not possess dental insurance coverage. This is regardless of whether the service is provided in the dental hospital or dental private practice.

The radiographs that constituted the two samples in this study were obtained from 84% of the institutions that perform panoramic radiography in Trinidad and Tobago. The results showed that 95.8% of panoramic radiographs in dental private practice examined in this study contained one or more positioning errors while in the dental hospital the percentage was 94.2%. Thus, the diagnostic benefits of the majority of these images were significantly reduced. Additional processing errors which also affect diagnostic yield were not included.

In this study, it was observed that the highest frequency of errors were due to rotation of the head (66.4%). This finding is in agreement with a previous study on evaluation of panoramic radiograph errors by Kaviani *et al* (9). Rotation of the head leads to discrepancies in horizontal magnification of integral structures and interferes with diagnostic interpretation. Careful attention must be paid to the position of the light beam marker for the mid-sagittal plane before the exposure is carried out.

The second most common error observed in this study was failure to place the tongue on the palate during the exposure (65.3%). This error has been reported to be the most common in two similar studies on panoramic errors by Akarlan *et al* (5) and Al-Faleh (11). A consequence of this error is superimposition of the air shadow above the tongue on the apices of the maxillary teeth. Superimposition of this shadow results in difficulty in interpretation of the periapical region of maxillary teeth. This error may be a result of failure of the operators to instruct the patients to place the tongue on the palate during the exposure. The importance of this instruction needs to be reinforced during the training of operators of panoramic radiography. However, one has to consider that even if instructed properly some patients may misunderstand the instructions or completely disregard them.

The limitations of this study include different machines with varying ages that were used to produce the radiographs analysed in the dental private practice sample whereas the same panoramic machine was used in the dental hospital. Radiographs produced with older machines may increase error rates because with extended use the location of the focal trough could change, necessitating recalibration if suboptimal images are consistently produced (17). Additionally, there were more operators in dental private practice than in the dental hospital which could have led to differences in error frequencies. However, although different machines were used and the number of operators varied between samples, each operator should be competent with the manufacturer's instructions on how to position the patient correctly in the focal trough to minimize errors.

The frequencies of errors in dental private practice were higher than in the dental hospital in all categories studied except for the "Chin tipped too low" category. All of the operators in dental private practice in this study were informally trained whereas those in the dental hospital received certification in radiography from a local institution. This is one explanation for the difference observed and supports the recommendation that formal training of all operators of dental radiography is required in this country. The finding of such a high overall frequency of errors in both settings clearly demonstrates that there is a larger problem than anticipated and calls into question the quality and standard of the formal certified training in the local institution and highlights the need for continuing education of formally trained operators.

The findings in this study also question the nature of the informal training undergone by the operators in dental private practice. Although all dentists in private practice would have undergone training in dental radiography as part of their undergraduate curriculum, the question arises whether or not this is sufficient for them to be the sole teachers of dental radiography to their staff.

The results of this study highlight that poor quality panoramic radiography is a prevalent problem in Trinidad and Tobago. At the present time, in this country, there is no

specific legislation outlining the training requirements of operators of dental radiography or that makes training mandatory. A possible reason for the lack of legislation governing the use of ionizing radiation in dental practice could be that the problems in this field have never been highlighted.

Without qualified operators, panoramic images can be likened to photographs taken by an amateur photographer. If all operators were to be formally trained and be provided opportunities for continuing education, the diagnostic tool of panoramic radiography will deliver greater value to the citizens of Trinidad and Tobago and should become comparable to standards in developed countries.

CONCLUSION

There are a multitude of factors that may lead to a reduction of the diagnostic quality of panoramic radiographs. Patient positioning errors are some of the most common. The results of this work clearly identify that there is a need to improve the quality of panoramic images taken in all institutions that offer this service in Trinidad and Tobago by improving the training that is provided for all types of operators.

ACKNOWLEDGEMENTS

The authors would like to thank Dr Bidyadhar Sa of the Centre for Medical Sciences Education, The University of the West Indies, Trinidad and Tobago for his assistance with this research.

REFERENCES

1. Yeo DK, Freer TJ, Brockhurst PJ. Distortions in panoramic radiographs. *Aust Orthod J* 2002; **18**: 92–8.
2. Kullman L, Joseph B. Quality of digital panoramic radiography in a newly established dental school. *Swed Dent J* 2006; **30**: 165–70.
3. Rumberg H, Hollender L, Oda D. Assessing the quality of radiographs accompanying biopsy specimens. *J Am Dent Assoc* 1996; **127**: 363–8.
4. Brown RS, Coleman-Bennett MM, Jones-Matthews T. Synthetic hair braid extension artifacts in panoramic radiographs. *J Am Dent Assoc* 1998; **129**: 601–4.
5. Akarlan ZZ, Erten H, Güngör K, Celik I. Common errors on panoramic radiographs taken in a dental school. *J Contemp Dent Pract* 2003; **4**: 24–34.
6. Schiff T, D'Ambrosio J, Glass BJ, Langlais RP, McDavid WD. Common positioning and technical errors in panoramic radiography. *J Am Dent Assoc* 1986; **113**: 422–6.
7. Brezden NA, Brooks SL. Evaluation of panoramic dental radiographs taken in private practice. *Oral Surg Oral Med Oral Pathol* 1987; **63**: 617–21.
8. Rushton VE, Horner K, Worthington HV. The quality of panoramic radiographs in a sample of general dental practices. *Br Dent J* 1999; **186**: 630–3.
9. Kaviani F, Johari M, Esmaceli F. Evaluation of common errors of panoramic radiographs in Tabriz Faculty of Dentistry. *JODDD* 2008; **2**: 99–101.
10. Mckee IW, Glover KE, Williamson PC, Lam EW, Heo G, Major PW. The effect of vertical and horizontal head positioning in panoramic radiography on mesiodistal tooth angulations. *Angle Orthod* 2001; **71**: 442–51.
11. Al-Faleh W. Common positioning errors in panoramic radiography. *Egyptian Dental Journal* 2005; **51**: 1813–17.
12. Langland O, Langlais R, Preece J. *Principles of dental imaging*. USA: Lippincot Williams & Wilkins; 2002.

13. Yates F. Contingency table involving small numbers and the χ^2 test. Supplement to the Journal of the Royal Statistical Society 1934; **1**: 217–35.
14. Altman DG. Practical statistics for medical research. London: Chapman and Hall; 1991.
15. National Radiological Protection Board. Guidance notes for dental practitioners on the safe use of X-ray equipment, UK: National Radiological Protection Board; 2001.
16. Ludlow JB, Davies-Ludlow LE, White SC. Patient risk related to common dental radiographic examinations. J Am Dent Assoc 2008; **139**: 1237–43.
17. Razmus TF, Glass BJ, McDavid WD. Comparison of image layer location among panoramic machines of the same manufacturer. Oral Surg Oral Med Oral Pathol 1989; **67**: 102–8.