

CASE REPORT

Lateral Medullary Infarct/Wallenberg Syndrome – Jamaica

T McGhie, R Alfred, A Ali, D Gilbert

ABSTRACT

We describe two cases of lateral medullary syndrome at the University Hospital of the West Indies, Mona, Jamaica. This diagnosis is often missed and not well understood, so we will discuss the underlying pathophysiology.

Keywords: Lateral medullary infarct, posterior circulation syndrome, Wallenberg syndrome

From: Department of Medicine, The University of the West Indies and the University Hospital of the West Indies, Kingston 7, Jamaica, West Indies.

Correspondence: Dr R Alfred, Department of Medicine, The University of the West Indies, Kingston 7, Jamaica, West Indies. E-mail: rose24_tt@yahoo.com

CASE A

AJ, a 52-year old male hypertensive for over 19 years and Type II diabetic for seven years with no known micro- or macrovascular complications of his chronic illnesses, presented to hospital with a two-hour history of left-sided headache: fronto-temporal and occipital. He reported that, on waking, he had sudden onset of headache – the worst headache he had ever experienced with pain to the left-side of the face – from forehead to chin. At that time, he noted dizziness – the sensation of himself spinning with the inability to stand.

He noted a tendency to fall to the left on attempts to ambulate. Shortly after the onset of the dizziness, he noted left-sided weakness involving both arms and legs simultaneously. In light of the above symptoms his family became concerned and took him to the Accident and Emergency (A&E) department for further management. On presentation to the A&E department, he had nausea and multiple episodes of vomiting of recently eaten food. He also noted at that time that he was experiencing diplopia – unable to recall the character of the diplopia. Over the next 1–2 hours in the A&E, he began to experience numbness to the left side of his face with the left eye closing down partially and he also noted slurred speech with changing of his voice to a more rasping sound. At that time, he had difficulty swallowing and he developed hiccups which persisted for several hours.

He had no facial twisting, abnormal limb movements, syncope or loss of consciousness as well as no palpitations, chest pain or shortness of breath. He had no history of abdominal pain or diarrhoea associated with the vomiting and he had no fever, neck stiffness or photophobia.

His past medical, surgical, family and social history was unremarkable. Presenting vital signs on arrival to hospital were blood pressure (BP) 223/130 mm Hg, pulse (P) 72 beats per minute, respiratory rate (R) 20/minute, temperature (T) 35.9 °C.

Urine dipstick revealed 3⁺ protein. His examination was significant for hypotonia in the left upper and lower limbs and a left hemiparesis with grade 4/5 power at all joints in the upper and lower limbs. The rest of his nervous system examination was documented as being normal. He was assessed as a hypertensive emergency and possibly, a haemorrhagic stroke and treated accordingly. His immediate investigations included computed tomography (CT) of the brain which was unremarkable and chest radiograph (CXR) which revealed a widened mediastinum.

His CT chest revealed an aneurysm from the aortic arch, with dissection from the root to L1 with the widest diameter at the level of L3– AP diameter 6.9 cm – with extensive atherosclerotic disease throughout the aorta. Echocardiogram revealed left ventricular hypertrophy (LVH) with normal coronary arteries. He was assessed by the cardiothoracic team as a likely chronic aortic dissection with aneurysmal formation.

The neurology team was invited to evaluate the patient for stroke when he was noted to have worsening of his left-sided weakness on day 14 of admission. He complained of worsening left-sided weakness since admission with persistent and gradual worsening of the presenting complaints especially the hiccups. In addition, he was experiencing severe dull burning pain with itchy sensation to the left half of the face with pain to the left ear which he attempted to relieve by rubbing the skin. At that time his vital signs were BP 125/75 mm Hg, P 74/min, R 22/min, T 35.8 °C.

Significant findings were confined to the skin of his face and the nervous system. He had excoriations to the left half of the face – frontalis, inferior orbital ridge, lateral nose and inferior

left nostril with associated erythema. The mental status examination was significant only for mild intermittent drowsiness.

The cranial nerve examination revealed left ptosis, left miosis 0.5 mm vs right 1.0 mm with left hemi anaesthesia for pain and light touch in the 1st and 2nd trigeminal division and a decreased gag response. The rest of the cranial nerve examination was unremarkable.

He had a left hemiparesis with grade 1 power at all muscle groups in the upper and lower limbs with asymmetric reflexes—1+ in the left upper and lower limbs and 2+ on the right with a left extensor plantar response.

Sensory examination revealed decreased pain sensation to the right lower limb and he displayed significant cerebellar signs – horizontal nystagmus, truncal ataxia, left dysmetria, left dysrhythmia and left dysdiadochokinesia.

He was assessed as having Lateral Medullary Syndrome secondary to either an embolic phenomenon or due to vertebral artery dissection on the background of his aortic dissection. A magnetic resonance imaging (MRI) was done which confirmed the diagnosis.

CASE B

DB, was a 60-year old right-handed male, with a history of controlled hypertension for five years, being followed by a general practitioner. He had 15 smoking pack years and had been on amlodipine 5 mg and co-aprovel 30/500 mg each once daily. There was no history of previous stroke or diabetes mellitus or ischaemic heart disease. He was well up until six days previously when he had a sudden bout of new onset vertigo, while standing. This was short lived, but returned later. Several episodes of non-projectile vomiting of undigested food followed, in

association with light headedness, dizziness and blurred vision: “things moving”. Subsequently, he experienced a new severe right-sided occipital headache with numbness to the right side of his face and difficulty keeping his balance. Slurred speech, dysphagia and hoarseness then ensued. There was no fever, neck stiffness, syncope or jerky movements noted.

He did give a history of previous headaches which were different from this new one. These were “burning” in nature and present for five years, involving the right frontal area, radiating to the temporal lobe, usually occurring twice a week. They were of moderate to severe intensity, relieved by diclofenac. Basilar symptoms were absent, and a CT brain done three years prior was reported as normal.

No known allergies to drugs existed and the past surgical history was only significant for benign prostatic hyperplasia, for which he was taking doxazosin 8 mg once daily, haemorrhoidectomy and exploratory laparotomy 40 years ago post-penetrating abdominal injury.

On examination, vital signs were blood pressure 149/94 mmHg, P 85/min, R 24/min, T 37.2 °C. He was diaphoretic. Significant findings were confined to the nervous system. Mental status examination was normal, except that he was dysphonic with a scanning dysarthria. For cranial nerves, pupils were equal, round and reactive to light and accommodation. Fundoscopy was normal. A Horner’s syndrome was evidenced by right-sided anhidrosis and right-sided ptosis. Third degree horizontal jerky and saccadic nystagmus was noted with square jerks in a left and downward direction. Facial sensation was normal. He had a right facial palsy of the upper motor neurone type. His tongue was central and his uvula was deviated towards the left. Muscle bulk and tone were normal. A right-sided pronator drift was seen. He exhibited a mild intention tremor, right-sided dysmetria, abnormal right heel to shin coordination, with

significant truncal ataxia towards the right side. Right-sided hyporeflexia and equivocal plantar response were also found. There was contralateral loss of pain and temperature on sensory examination. At that point, he was assessed as having right-sided cerebellar ischaemic infarct involving the posterior inferior circulation.

His routine blood investigations and thyroid function tests were normal. However, his low-density lipoprotein (LDL) was 2.65 mmol/L. Magnetic resonance imaging of the brain (Fig. 4) revealed an infarct (2.5 x 1.4 cm on CT) extending to involve the right cerebellar tonsil and right side of the medullary and spinomedullary junction, corresponding to the right posterior inferior cerebellar artery. There were multiple non-specific small vessel ischaemic changes in the bilateral frontal lobes. The ventricles, extra-axial areas, orbits, petrous temporal bones and skull bases were normal.

Intravenous hydration was given to maintain his blood pressure. Aspirin 325 mg once daily with dipyridamole 75 mg thrice daily were instituted. Anti-emetic and physiotherapy were employed and his symptoms gradually subsided within five days. He had residual sensory loss, with partial anhidrosis and limb ataxia on discharge.

DISCUSSION

Lateral medullary syndrome is also called Wallenberg's syndrome, after the eminent Adolf Wallenberg, a German physician and neuroanatomist who gave an accurate description of the pathology of the syndrome in 1901 after an autopsy (1). It may also be called posterior inferior cerebellar artery (PICA) syndrome. It is the most common and important syndrome related to intracerebral vertebral artery (ICVA) occlusion (2). It encompasses several symptoms due to a neurological disorder of the nuclei and nerve tracts located in the lateral part of the medulla. The underlying cause is usually infarction secondary to occlusion of the vertebral artery. Isolated involvement of the PICA is a less common cause.

The diagnosis is often missed by non-neurologists, and so the features are very important to know and understand. It may also involve infarction of the posterior cerebellum (3), and a minority of cases may be due to occlusion of the posterior inferior cerebellar artery. Causes include atherothrombotic occlusions, most commonly, but traumatic vertebral artery dissection may be a causative factor (4). Rarer causes may be linked to infections, such as skull base osteomyelitis (5) or tropical neurocysticercosis (6). Demyelination in multiple sclerosis (7) and autoimmune conditions, such as Sjroger's syndrome (8) have also been associated.

Various tracts are affected and as such, patients present with multiple manifestations. Involvement of the vestibular nucleus causes rotational and horizontal nystagmus, diplopia, oscillopsia, vertigo, nausea and vomiting. The rapid phase of the rotatory nystagmus usually moves the upper border of the iris towards the side of the lesion. Most often, larger amplitude, slower horizontal nystagmus is present on gaze to the side of the lesion, while smaller amplitude, quick nystagmus is found on gaze directed to the contralateral side.

The most disabling features are ipsilateral ataxia caused by infarction of the inferior cerebellar peduncle and vertigo from infarction of the vestibular nuclei. Disease of the spinocerebellar tract leads to limb ataxia and the feeling of falling towards the side of the lesion.

Descending sympathetic fibres which run in close proximity to the spinothalamic tract in the lateral tegmentum of the brainstem may be involved, giving rise to an ipsilateral Horner's syndrome: partial ptosis, miosis and less commonly anhidrosis. Autonomic dysfunction may also occur in the form of diaphoresis and tachycardia, bradycardia and orthostasis.

Paralysis of the palate and vocal cord (the ninth and tenth cranial nerves) is related to the dysphagia, hoarseness and diminished gag reflex. Stridor has been described (9). Loss of taste stems from the nucleus and tractus solitarius. The nucleus ambiguus which lies just dorsal to the inferior olivary nucleus supplies branchial motor fibres that travel in the vagus nerve to the muscles of the palate, pharynx and larynx, and in the glossopharyngeal to the stylopharyngeus. Infarction of the nucleus and exiting fascicles of cranial nerve IX cause breathy hoarseness and dysphagia and the gag reflex is often decreased on the side of the lesion, and laryngoscopy shows ipsilateral vocal cord paralysis.

Hiccups (singultus) are an infrequent result of lateral medullary infarction; however, the anatomical lesion of hiccups is not well known (10). Hiccups are repeated, involuntary, spasmodic contractions of the diaphragm accompanied by sudden closure of the glottis, producing a distinguishing "hic" sound. The relation between the lesion loci of lateral medullary infarction and hiccups was evaluated in 51 patients who were investigated by MRI within three days of the onset of infarction. Seven of the 51 patients developed hiccup. All patients with hiccups had middle level lateral medullary lesions, including two with lower level lesions and four with upper level lesions. In the middle level lesions, dorsolateral lesions were most often

involved. These observations suggest that middle level and dorsolateral lesion locations frequently induce hiccups. There was a close correlation between hiccups and symptoms of cerebellar, vestibular, and fifth, ninth and tenth cranial nerve involvement.

The spinal trigeminal nucleus which is the rostral extension of the dorsal horn conveys sensory information: crude touch, pain and temperature. This nucleus extends from the lateral midpons to the cervical spinal cord at the level of C3 and its involvement results in ipsilateral loss of touch, pain and temperature sensation from the face because the primary sensory fibres do not cross before entering the nucleus.

Involvement of the lateral spinothalamic tract results in contralateral deficits in pain and temperature sensation from the body. The cuneate and gracilis nuclei are linked to the numbness of the ipsilateral arm, trunk and leg.

In a case series with "blinded" evaluation of brain imaging to correlate clinical and radiologic findings in patients with lateral medullary infarction, thirty-three consecutive patients with lateral medullary syndrome were evaluated by the Stroke Centre between 1983 and 1989. The triad of Horner's syndrome, ipsilateral ataxia and contralateral hypalgesia was shown to clinically identify patients with lateral medullary infarction. Facial weakness and ocular symptoms are frequent and do not necessarily imply that the infarction extends beyond the lateral medulla. Also of note was the fact that vertebral artery disease was confirmed by vascular imaging or ionization studies in 73% of patients and cerebellar infarcts were found to only infrequently accompany lateral medullary syndrome, suggesting that most of the posterior inferior cerebellar artery territory is spared, despite the high frequency of vertebral artery occlusion (11).

Hemiplegia is uncommon, but may be related to involvement of the corticospinal tract as it passes through the medulla. This may be seen in vertebral artery dissection – Opalski syndrome (12).

A review of the reports of hemimedullary syndrome in the literature and comparison of the characteristics of patients with dissection of the vertebral artery (VA) with those with VA atherosclerotic disease revealed that dissection of the VA may provoke a hemimedullary lesion at a level lower than atherosclerosis, thus affecting medullary-penetrating branches that irrigate the medulla immediately below the pyramidal decussation (13).

Because the syndrome affects the lateral tegmentum, motor involvement is usually not prominent. However, in some cases, there may be ipsilateral facial weakness, possibly due to fibres of the facial nerve that loop caudally into the medulla before exiting at the pontomedullary junction (13). Additionally, infarcts that extend medially, reaching the pyramidal tract, may cause contralateral hemiparesis. An ipsilateral hemiparesis may represent a very rare entity – hemimedullary (Reinhold) syndrome which combines the clinical features of lateral and medial medullary infarctions as a result of hemi-infarction of the medulla (14). Case B was noted to have ipsilateral hemiparesis. This may have been present before from a previous stroke or involvement of the medial medulla. The relatively small size of his infarct may have caused such profound symptoms because of surrounding mass effect. Medial medullary syndrome reflects the involvement of the following structures: the nucleus and rootlets of the hypoglossal nerve, medial longitudinal fasciculus, medial lemniscus and pyramid.

CONCLUSION

Lateral medullary syndrome is a disorder of the posterior cerebrovascular circulation and has implications on one's activity of self-caring. It does not commonly cause a hemiparesis. As such, one should be quick to recognize these symptoms and manage the patient appropriately, making sure to rule out dissection of the vessel involved.

REFERENCES

1. Blumenfeld H. Neuroanatomy through clinical cases. Sunderland, MA: Sinauer; 2002.
2. Caplan L. Posterior circulation ischemia: then, now, and tomorrow. The Thomas Willis Lecture–2000. *Stroke* 2000; **31**: 2011–23.
3. Kasper DL, Braunwald E, Fauci AS, Hauser SL, Longo DL, Jameson JL. Harrison's Principles of Internal Medicine. 16th edition. McGraw Hill Medical Publishing; 2005.
4. Yeh HF, Seak CJ, Chiu TF, Chang YC. Traumatic vertebral artery dissection and Wallenberg syndrome after a motorcycle collision. *Am J Emerg Med* 2009; **27**: 131 e1–3.
5. Ng J, Connolly DJ, Rittey C, Mordekar S. Skull base osteomyelitis leading to lateral medullary syndrome in a child. *Eur J Paediatr Neurol* 2007; **11**: 111–4.
6. Napon C, Ouédraogo D, Diallo O, Kaptó O, Kabore J. Wallenberg syndrome and neurocysticercosis: about one case in Ouagadougou, Burkina Faso. *Bull Soc Pathol Exot* 2009; **102**: 5–6.
7. Qiu W, Wu JS, Carroll WM, Mastaglia FL, Kermode AG. Wallenberg syndrome caused by multiple sclerosis mimicking stroke. *J Clin Neurosci* 2009; **16**: 1700–2.
8. Mehta P, Fernando MM, Pickering MC, Wilson Y, Molloy S, Colaco CB. Lateral medullary syndrome with anti-neuronal antibodies (anti-Ta/Ma2) in primary Sjogren's syndrome. *Rheumatology (Oxford)* 2009; **48**: 1174–6.
9. Vaidyanathan S, Capper R, Chadha D. Stridor: an unusual presentation of lateral medullary syndrome. *J Laryngol Otol* 2007; **121**: e9.
10. Park MH, Kim BJ, Koh SB, Park MK, Park KW, Lee DH. Lesional location of lateral medullary infarction presenting hiccups. *J Neurol Neurosurg Psychiatry* 2005; **76**: 95–8.
11. Sacco RL, Freddo L, Bello JA, Odel JG, Onesti ST, Mohr JP. Wallenberg's lateral medullary syndrome. Clinical-magnetic resonance imaging correlations. *Arch Neurol* 1993; **50**: 609–14.

12. García-García J, Ayo-Martín O, Segura T. Lateral medullary syndrome and ipsilateral hemiplegia (Opalski syndrome) due to left vertebral artery dissection. *Arch Neurol* 2009; **66**: 1574–5.
13. Porto FH, da Silva S, Orsini M, de Freitas MRG, de Freitas GR. Hemimedullary infarct with ipsilateral hemiplegia: a vertebral artery dissection syndrome? *J Neurol Sci* 2009; **278**: 135–7.
14. Mossuto-Agatiello L, Kniahynicki C. The hemimedullary syndrome: case report and review of the literature. *J Neurol* 1990; **237**: 208–12.

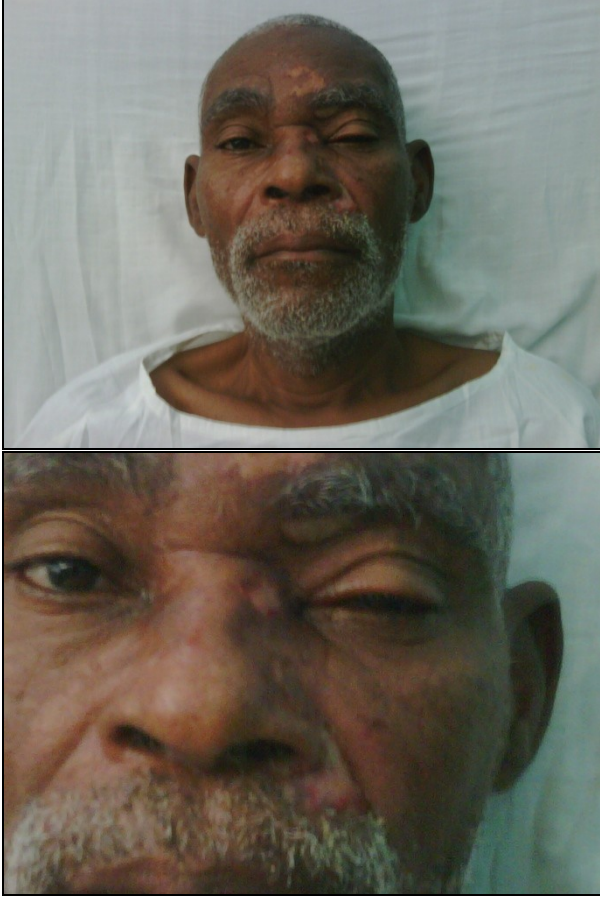
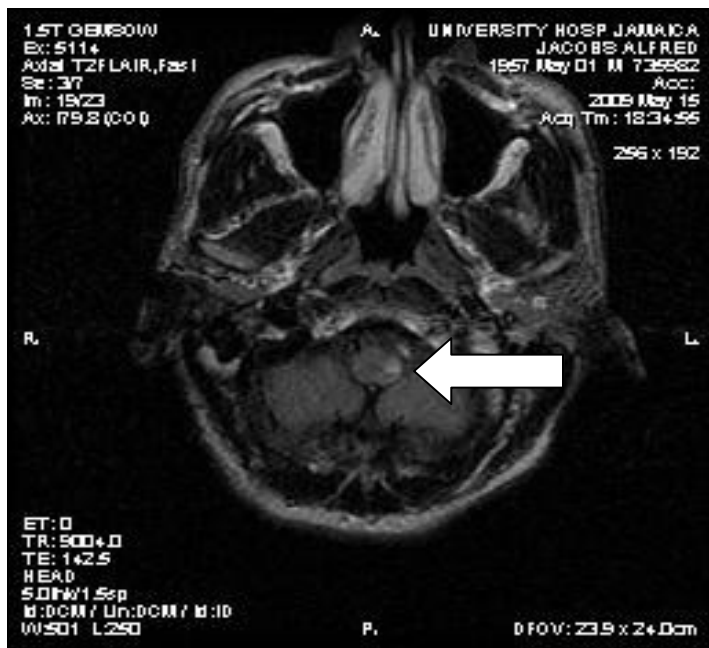
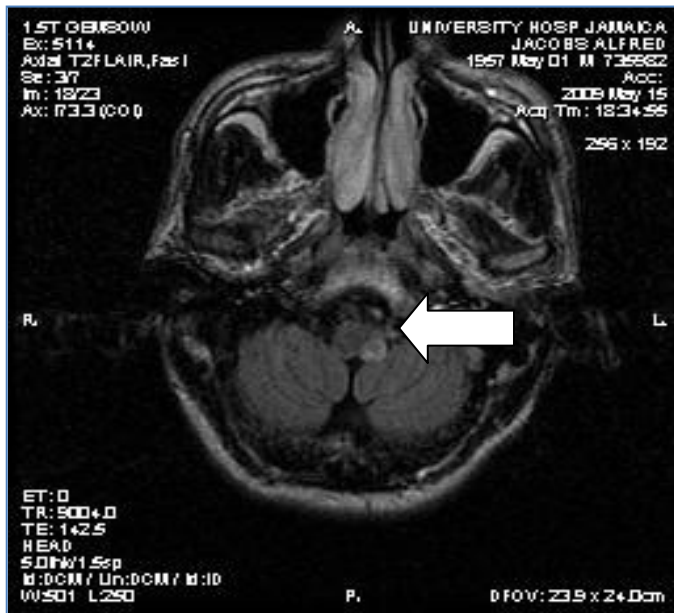Fig. 1: Ipsilateral ptosis noted with superficial ulceration to the involved side of the face.



Figs. 2 and 3: Magnetic resonance imaging scans showing infarction – Case A.

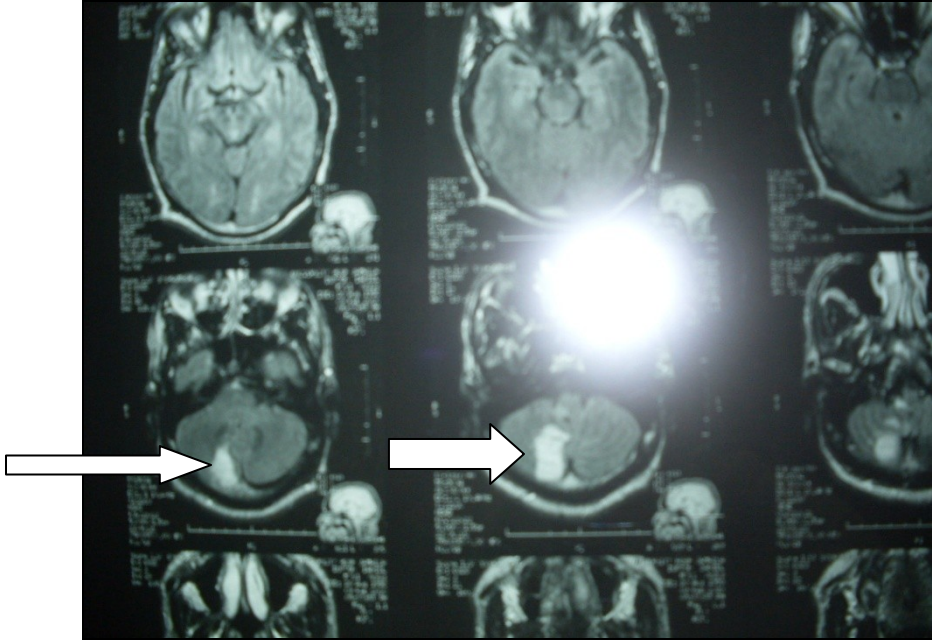


Fig. 4: Magnetic resonance imaging scans showing infarction – Case B.