

A Case Report: Successful Treatment of Meningeal Metastasis with Concurrent Whole Brain Radiotherapy and Erlotinib in a Patient with Non-small Cell Lung Cancer

J Huang¹, X-R Dong¹, H-D Lu², L Liu¹

ABSTRACT

We report a case of successful treatment with erlotinib of a patient with non-small cell lung cancer (stage IV) and meningeal metastasis. Combined treatment with whole brain radiotherapy (WBRT) and erlotinib mitigated neurologic symptoms of the patient. Magnetic resonance imaging showed reduction of the brain metastasis. Partial remission was observed by chest computed tomography (CT) scan after six months of erlotinib therapy.

Key words: Erlotinib, magnetic resonance imaging, non-small cell lung cancer, whole brain radiotherapy

Reporte de Caso: Tratamiento Exitoso de una Metástasis Meníngea con Radioterapia Total Concurrente del Cerebro y Erlotinib en un Paciente con Cáncer Pulmonar de Células no Pequeñas

J Huang¹, X-R Dong¹, H-D Lu², L Liu¹

RESUMEN

Reportamos un caso de tratamiento exitoso con el erlotinib de un paciente con cáncer pulmonar de células no pequeñas (fase IV) y metástasis meníngea. El tratamiento combinado con la radioterapia total del cerebro (WBRT) y erlotinib mitigaron los síntomas neurológicos del paciente. Las imágenes de resonancia magnética mostraron una reducción de la metástasis del cerebro. La remisión parcial fue observada mediante CT scan de tórax tras seis meses de terapia con erlotinib.

Palabras claves: Erlotinib, imagen por resonancia magnética, cáncer pulmonar de células no pequeñas, radiografía total del cerebro

West Indian Med J 2012; 61 (1): 106

INTRODUCTION

Meningeal metastasis occurs in approximately 5% of breast cancers, which produces high neurologic morbidity and mortality (1). Therapies usually include radiotherapy, intrathecal chemotherapy and systemic chemotherapy. However, treatment is often ineffective. Most untreated patients can only survive a median of four to six weeks (2). Standard treatment only increases the median survival to 3–6 months (3). Combined chemotherapy and radiotherapy may produce an enhanced effect.

From: ¹The Cancer Centre of Union Hospital, Tongji Medical College of Huazhong University of Science and Technology, Wuhan 430023, China and ²Tongji Medical College of Huazhong University of Science and Technology, Wuhan 430030, China.

Correspondence: Dr L Liu, The Cancer Center of Union Hospital, No. 156 Wu Jia-dun, Jiangnan District, Wuhan 430023, Hubei Province, China. E-mail: liul_hust@163.com

CASE REPORT

We report a patient with meningeal metastasis responding to concurrent whole brain radiotherapy and erlotinib. A 67-year old Chinese man without a smoking history was diagnosed with T1N2M1 stage IV non-small-cell lung cancer (NSCLC) with bone metastasis in November 2007. During a medical examination in November 2007, the patient was found to have a mass in his right upper lung. After undergoing bronchoscopy and position emission tomography-computed tomography (PET-CT), he was diagnosed with adenocarcinoma of the lung with bone metastasis. The patient immediately received first-line treatment with carboplatin (area under the curve 6) and paclitaxel (175 mg/M² every three weeks). After six cycles of chemotherapy, a partial remission of the primary disease in his chest was achieved as demonstrated by CT scan.

In September 2008, however, he experienced headache, progressive visual loss, unsteady gait and temporary absence

seizure. Brain magnetic resonance imaging (MRI) with a Gd-DTPA administration showed an abnormal meningeal enhancement in the occipital lobe on T1-weighted imaging (Fig. 1A) and papilloedema was noted on fundusoscopic examination.

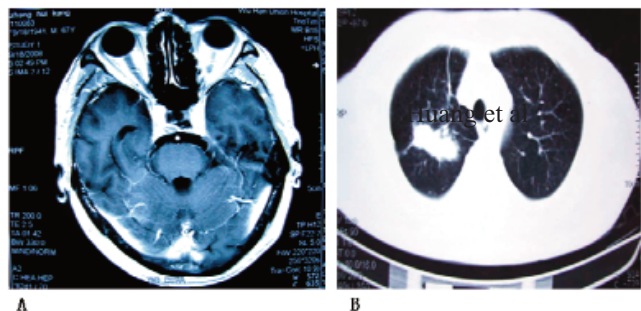


Fig. 1: Images taken before erlotinib

A: Brain MRI with a Gd-DTPA administration, T1-weighted imaging. An abnormal meningeal enhancement in the occipital lobe is shown.
B: Chest CT scan. A nodular shadow with spicule formation in the upper right lung is shown.

A lumbar puncture was performed and the cerebrospinal fluid (CSF) proved to be positive for adenocarcinoma cells. Computed tomography imaging confirmed tumour progression in the right lung (Fig. 1B), coupled with abnormal levels of tumour markers detected by medical laboratory tests (Table).

Table: The expression of serum tumour markers before and during treatment

Tumour mark	Before treatment (18 Sep 2008)	During treatment (23 Oct 2008)
CEA (ng/ml)	36.8 ± 4.18	13.3 ± 2.69
CA-125 (U/ml)	67.8 ± 7.54	20.9 ± 3.71
CA-199 (U/ml)	103.4 ± 11.86	14.1 ± 1.95

· Compared with serum tumour marker levels before treatment, the differences are statistically significant.

Due to his poor performance status, the patient received whole brain radiotherapy (WBRT) [36Gy/12F] with concurrent Tarceva 150 mg daily. After a week's treatment, his headaches began to ease and then disappeared, while his sight improved gradually. The levels of tumour markers returned to normal in late October 2008 (Table). After completion of the WBRT, MRI with Gd-DTPA administration indicated that the high-intensity signals were largely diminished in T1-weighted imaging (Fig. 2A), and the patient was discharged at the end of October 2008 and continued to receive erlotinib as an outpatient.

When the patient returned for review with CT result in March 2009, he presented with a significantly improved physical condition. The chest CT scan (Fig. 2B) showed that there was partial response as assessed by the RECST guidelines. Treatment was well tolerated, and the adverse effects were

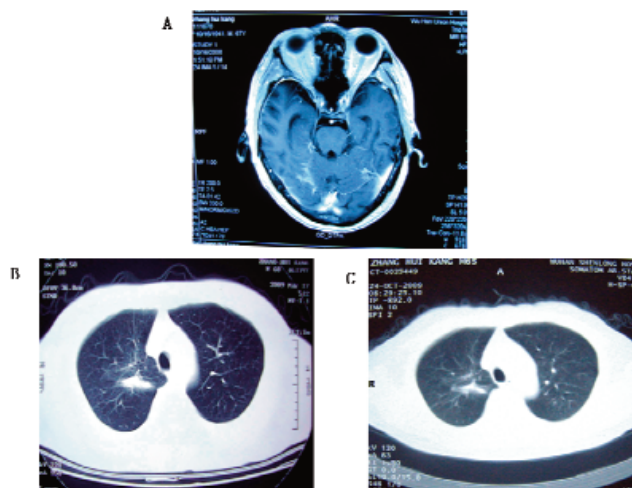


Fig. 2: Images taken during erlotinib

A: Brain MRI taken on 16 October 2008. High-intensity signals have largely diminished.
B: Chest CT scan on 17 March 2009. The nodular shadow had decreased.
C: Chest CT scan on 24 October 2009. The regressed size of the nodular shadow was maintained.

minimal rash and low-grade diarrhoea. The patient had good performance status, and the size of the primary lung tumour did not enlarge for more than one year (Fig. 2C, chest CT scan in late October 2009).

DISCUSSION

Brain metastasis is a common complication in patients suffering from NSCLC. Autopsy studies have shown that approximately 44% of all patients with NSCLC have brain metastasis during the course of the illness.

Meningeal metastasis was first recognized by Eberth in 1870 and was initially thought to be rare as it was uncommonly diagnosed before death. However, the reported incidence of this advanced complication is likely to increase due to advances in neuroimaging techniques and the long survival of cancer patients.

The characteristics of the disease involve various levels of the nervous system, including encephalic, cranial or spinal nerve and spinal symptoms. Sudden loss of vision or hearing is the initial sign of the disease which may progress rapidly. Headache, changes in mental status, cranial nerve palsies, back or radicular pain, incontinence, lower motor neurone weakness, and sensory abnormalities are all common presenting findings.

Although CT and nuclear magnetic resonance may aid in the diagnosis of this condition, only the presence of malignant cells in the CSF is considered to be the gold standard in the diagnosis of meningeal metastasis (4).

The treatment for meningeal metastasis includes radiotherapy, intrathecal chemotherapy and systemic chemotherapy. However, no effective drug for NSCLC has been approved as safe for intrathecal injection. Whole brain radiotherapy, the so-

called 'gold-standard in the treatment of brain metastasis', is effective, but its impact on survival seems to be limited (5).

Erlotinib (Tarceva, OSI-774) is an orally available small-molecule inhibitor of the epidermal growth factor receptor (EGFR) tyrosine kinase. Similar to gefitinib, erlotinib is designed to block tumour cell growth by targeting the protein of human epidermal growth factor receptor 1 (HER1/EGFR). Erlotinib has demonstrated a survival benefit in patients treated for lung cancer in phase III trials. It was approved by the Food and Drug Administration (FDA) in 2004 for the treatment of locally advanced or metastatic NSCLC that has failed at least one prior chemotherapy regimen.

Eight case reports have described the clinical efficacy of Tarceva in patients with central nervous system (CNS) metastasis (6). In most reports, patients' brain lesions responded to Tarceva. Rash was documented in several reports including one case of acute generalized exanthematous pustulosis (AGEP), a case of Grade 3 acneiform skin rash, radiodermatitis, elevated liver enzymes, vertigo and one fatal case of bilateral subdural haemorrhage.

In a phase I study by Lind *et al*, WBRT with concurrent erlotinib was well tolerated in patients with brain metastasis from NSCLC (7). Mairovitz *et al* published a case report of a patient diagnosed with NSCLC with bone and brain metastasis, who presented a complete cerebral response for 17 months with erlotinib prescribed as a third line therapy (8).

In the present study, erlotinib showed good effect and good tolerance on metastatic lesions in the CNS from NSCLC. However, there are still few reports about meningeal metastasis, partly due to its low incidence and poor effect. In this case,

the patient was treated with WBRT in combination with erlotinib. Then erlotinib was used as maintenance treatment. The patient has survived for more than one year without progression. No serious adverse effect was found during the treatment. These results suggest that WBRT in combination with erlotinib may be a beneficial therapy for meningeal metastasis in NSCLC and deserves further study.

REFERENCES

1. DeAngelis LM. Current diagnosis and treatment of leptomeningeal metastasis. *J Neurooncol* 1998; **38**: 245–52.
2. Wasserstrom WR, Glass JP, Posner JB. Diagnosis and treatment of leptomeningeal metastases from solid tumors: Experience with 90 patients. *Cancer* 1982; **49**: 759–72.
3. Lagerwaard FJ, Levendag PC, Nowak PJ, Eijkenboom WM, Hanssens PE, Schmitz PI. Identification of prognostic factors in patients with brain metastases: a review of 1292 patients. *Int J Radiat Oncol Biol Phys* 1999; **43**: 795–803.
4. Chamberlain MC. Neoplastic meningitis. *J Clin Oncol* 2005; **23**: 3605–13.
5. Coia LR. The role of radiation therapy in the treatment of brain metastases. *Int J Radiat Oncol Biol Phys* 1992; **23**: 229–38.
6. Lai C-SL, Boshoff C, Falzon M, Lee SM. Complete response to erlotinib treatment in brain metastases from recurrent NSCLC. *Thorax* 2006; **61**: 91.
7. Lind JS, Lagerwaard FJ, Smit EF, Senan S. Phase I study of concurrent whole brain radiotherapy and erlotinib for multiple brain metastases from non-small-cell lung cancer. *Int J Radiat Oncol Biol Phys* 2009; **74**: 1391–6.
8. Mairovitz A, Staub E, Le Floch H, Rivière F, Bonnichon A, Margery J *et al*. Erlotinib and nonsmall cell lung cancer with brain metastasis: A case study with a complete and prolonged response over 17 months. *Rev Pneumol Clin* 2009; **65**: 318–21.