

## **Another Small Supernumerary Marker Chromosome Derived From Chromosome 9 in a Klinefelter Patient**

T Gulten, O Gorukmez, O Gorukmez, M Karkucak, M Ture, T Yakut

### **ABSTRACT**

Marker chromosomes are very rare in Klinefelter patients and phenotypic findings are related to the affected chromosomal region. The phenotypic effects of small supernumerary marker chromosomes (sSMC) range from multiple malformations/mental retardation to no effect (*ie* a normal phenotype). This wide spectrum of phenotypes is due to the origin, structure and gene content of the marker chromosome. The first Klinefelter case with sSMC 9 was published by Liehr *et al* in 2005. The present case was referred for chromosomal analysis because of dysmorphic features, speech delay and mild mental retardation. Conventional cytogenetic analysis revealed the 47 XXY karyotype in 17 metaphases and the 48 XXY + marker karyotype in eight metaphases. Fluorescence in situ hybridization (FISH) analysis to identify the marker chromosome was performed using the LSI p16 (9p21) Spectrum Orange/CEP 9 SpectrumGreen Probe (Vysis CDKN2A/CEP 9 FISH Probe) partial trisomy 9 mosaicism was confirmed in this patient. To our knowledge, this is the second Klinefelter syndrome case with a small supernumerary marker chromosome derived from chromosome 9.

**Keywords:** Fluorescence in situ hybridization (FISH) analysis, Klinefelter syndrome, small supernumerary marker chromosome

---

From: Uludag University, Medical Faculty, Medical Genetics Department, Turkey.

Correspondence: Dr T Gulten, Uludag University, Medical Faculty, Medical Genetics Department, 16059 Gorukle / Bursa, Turkey. E-mail: tunag@uludag.edu.tr

## INTRODUCTION

Klinefelter syndrome is the most common sex chromosome abnormality in humans. The 47 XXY genotype is frequently observed in individuals with Klinefelter syndrome, but the 48 XXXY, 48 XXYY and 49 XXXXY genotypes are also observed, though at very low frequencies. Signs vary with age (1). Most individuals with Klinefelter syndrome are of normal intelligence, but they may have low verbal scores and diminished speech abilities (2). The known genotypic variants of Klinefelter syndrome include 48 XXYY, 48 XXXY and 49 XXXXY. In addition to these common variants, the 47 XY, i(X) (q10) karyotype was reported as another variant genotype of Klinefelter syndrome (3).

Genetic aberrations accompanying Klinefelter syndrome include chromosomal aberrations such as double aneuploidies, rare mosaicisms and mosaicism of variant genotypes and some syndromes derived from the unbalanced transmission of balanced genetic structures from the parents (4–6).

Marker chromosomes are very rare in Klinefelter cases. The present case was evaluated for mental retardation and speech delay and had a mosaic karyotype of 48 XXY, +marker [8] /47 XXY [17].

## CASE REPORT

A 4-year old male was referred for chromosomal analysis because of dysmorphic features, speech delay and mild mental retardation. There were no extraordinary findings in the pedigree analysis, and his parents were not consanguinous. The child had low-set and slightly malformed ears, a broad and depressed nasal root, micrognathia, down-slanting palpebral fissures, a broad forehead, a short neck and left testicular atrophy. His brain magnetic resonance imaging (MRI) was compatible with the sequelae of global injury.

His karyotype was detected as 48 XXY, +marker [8]/47 XXY [17] using conventional cytogenetic analysis. Fluorescence in situ hybridization (FISH) analysis revealed the origin of the marker as chromosome 9.

Peripheral venous blood was cultured in RPMI-1640 supplemented with 2% glutamine, 10% fetal calf serum, and 2% PHA-M for 72 hours at 37 °C. Cultures were then treated with 0.1 ml (10 µg/ml) colcemid for 45 minutes, and the cells were harvested using a standard procedure. Prepared slides were kept in a 37 °C incubator for three days before trypsin Giemsa (GTG) banding. The karyotypes were defined according to the International System for Human Cytogenetic Nomenclature (ISCN, 1995). Conventional cytogenetic analysis revealed the 47 XXY karyotype in 17 metaphases and the 48 XXY + marker karyotype in 8 metaphases.

Fluorescence in situ hybridization analysis to identify the marker chromosome was performed with the following probes: Vysis CEP 4 (Aqua), CEP 6 (Green), CEP 10 (Orange), CEP 8 (Aqua), CEP 12 (Orange), 7q31/CEP 7, LSI p16 (9p21) Spectrum Orange/CEP 9 SpectrumGreen (Vysis CDKN2A/CEP 9 FISH Probe) and TOP2A/CEP 17.

In some of the cells, using the LSI p16 (9p21) Spectrum Orange/CEP 9 SpectrumGreen Probe (Vysis CDKN2A/CEP 9 FISH Probe), two signals belonging to 9p21

and three signals belonging to the CEP 9 region were detected (Figs. 1, 2). This finding confirmed the partial trisomy 9 mosaicism in this patient.

The ratios of mosaicism determined by FISH analysis and conventional cytogenetic analysis were nearly the same.

## DISCUSSION

Small supernumerary marker chromosomes (sSMC) are small, additional and structurally abnormal chromosomes. Conventional cytogenetic analysis is not sufficient to identify sSMCs because of their small size. Fluorescence in situ hybridization analysis is performed to determine their origin. The phenotypic effects of sSMCs range from multiple malformations/mental retardation to no effect (*ie* a normal phenotype). This wide spectrum of phenotypes is due to the origin, structure and gene content of the marker chromosome (7).

In numerically abnormal karyotypes, sSMCs were most often observed for individuals with Turner, Down, Klinefelter syndromes and Triple X (2, 7). The present case is the 4<sup>th</sup> Klinefelter syndrome case with a small supernumerary marker chromosome reported in the literature.

The first Klinefelter case with a marker chromosome was presented in 1997 by Manea *et al.* That patient was 2.5 years old and had a mos 48 XXY, + r(?X)/47 XXY karyotype. He had growth and developmental delay, microcephaly and microphallus. The origin of the marker was determined to be the X chromosome without the XIST (X-inactive specific transcript) region by FISH analysis (8).

In 2005, Liehr *et al* presented the second case. The karyotype of that patient was 48 XXY, +mar as determined by conventional cytogenetic analysis, and the marker's origin was identified as chromosome 9 by FISH analysis. The marker was dicentric and included the 9p12-q11.1 region. Inversion of the 9q11 duplication was suggested to be the formation mechanism of this marker. The 34-year old patient had bilateral gynecomastia, hypogonadism and azoospermia, which were compatible with Klinefelter syndrome. His bronchial carcinoma was not associated with the marker chromosome because there are no known oncogenes in the 9p12→q11.1 region; in addition, the patient has a history of smoking and of past exposure to asbestos (7).

In 2005, Weimer *et al* presented another Klinefelter case with two different marker chromosomes. The patient was ten years old and phenotypically male. He had mildly dysmorphic facial features, learning difficulties and severe speech delay. The karyotype was determined to be 48 XX, +mar1, +mar2[68]/47 XX, +mar1[19]/47 XX, +mar2[6]/46 XX[8] using conventional cytogenetic analysis. Marker chromosomes were identified using chromosomal microdissection, locus-specific FISH and polymerase chain reaction (PCR) techniques. According to the results, one of the marker chromosomes was a ring Y chromosome with the SRY region, and the other was the pericentromeric region of chromosome 8 (2).

In the present case, the marker chromosome looked like a large dot with a heterochromatic centre surrounded with euchromatin. It was suggested that this heterochromatic region was a centromere surrounded by a pericentromeric region. Fluorescence in situ hybridization analysis was performed using centromeric probes. In some cells, two signals for the 9p21 region and three signals for the CEP 9 region were observed in the FISH analysis using the LSI p16 (9p21) SpectrumOrange/CEP 9 SpectrumGreen probes. The result was indicative of mosaic partial trisomy 9.

In partial 9 trisomies, the phenotypic findings are related to the affected chromosomal region. The pericentromeric region of chromosome 9, which takes part in the structural rearrangements, is highly polymorphic. 9p21, 9p11, 9q12 and 9q13 are involved in different types of pericentric rearrangements, and they play roles in the formation of marker chromosomes originating from the 9<sup>th</sup> chromosome (9). In most of the 9p partial trisomy cases, mental retardation, growth retardation, microbrachycephaly, deep-set eyes, down-slanting palpebral fissures, a bulbous nose tip, low-set ears, brachydactyly, nail hypoplasia, and clinodactyly are common findings. These signs and symptoms can change according to the content of the trisomic part of the chromosome. Some individuals with 9p partial trisomy

exhibit only minor malformations and have a normal IQ and some exhibit no malformations or signs except infertility (10).

In the present case, the mosaic marker chromosome does not contain the 9p21 region, but its centromere is intact. The marker chromosome looks like a heterochromatic dot surrounded by a euchromatic region in conventional cytogenetic analysis. It may be possible to speculate that the marker chromosome involves the 9p13-q13 regions because its size is too small to involve the 9q21 and 9q22 regions. In addition, a heterochromatic region that would be indicative of the 9q21 region was lacking, and pyloric stenosis, which is characteristic of the presence of 9q22, was not observed.

The phenotypic features of the patient included low-set and minor malformed ears, a broad and depressed nasal root, micrognathia, down-slanting palpebral fissures, a broad forehead, a short neck and left testicular atrophy. In addition, there was speech delay and mild mental retardation.

To our knowledge, this is the 2<sup>nd</sup> case of Klinefelter syndrome with a small supernumerary marker chromosome derived from chromosome 9. However, the mosaic establishment and the content of the marker chromosome make this case unique. We suggest that each new case will provide additional information for more precise genotype-phenotype correlations for dysmorphic syndromes.

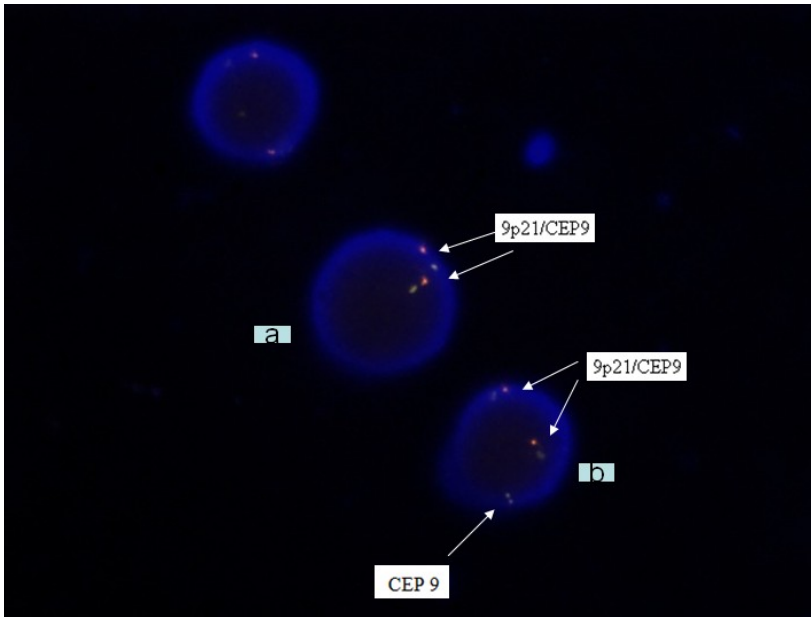


Fig. 1: Fluorescence in situ hybridization (FISH) analysis using LSI p16 (9p21) Spectrum Orange/CEP 9 SpectrumGreen Probe (Vysis CDKN2A/CEP 9 FISH Probe) demonstrates signals in two interphase cells (a and b). Orange (red) signals indicate the LSIp16 probe hybridization to short arm of chromosome 9 (9p21), and green signals indicate the CEP probe hybridized to centromeric region of chromosome 9. Cell (b) has partial trisomy 9 in addition to two intact chromosomes 9. Cell (a) does not have partial trisomy 9.



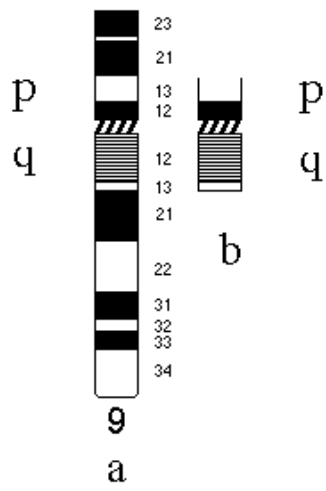


Fig. 2: This schematic figure shows the intact chromosome 9 (a) and the speculated regions of marker chromosome (b).

## REFERENCES

1. Visootsak J, Graham JM. Klinefelter syndrome and other sex chromosomal aneuploidies. *Orphanet Journal of Rare Diseases* 2006; **1**: 42. doi:10.1186/1750-1172-1-42.
2. Weimer J, Metzke-Heidemann S, Plendl H, Caliebe A, Grunewald R, Ounap K et al. Characterization of two supernumerary marker chromosomes in a patient with signs of Klinefelter syndrome, mild facial anomalies, and severe speech delay. *American Journal of Medical Genetics* 2006; **140A**: 488–495.
3. Stemkens D, Broekmans FJ, Kastrop PMM, Hochstenbach R, Smith BG, Giltay JC. Variant Klinefelter Syndrome 47 X,i(X)(q10),Y and normal 46 XY Karyotype in monozygotic adult twins. *American Journal of Medical Genetics* 2007; **143A**: 1906–1911.
4. Karaman A, Kabalar, E. Double aneuploidy in a Turkish child: Down–Klinefelter syndrome. *Congenital Anomalies* 2008; **48**: 45–7.
5. Delicado A, Lapunzina P, Palomares M, Molina MA, Galán E, Pajares IL. Beckwith–Wiedemann syndrome due to 11p15.5 paternal duplication associated with Klinefelter syndrome and a “de novo” pericentric inversion of chromosome Y. *European Journal of Medical Genetics* 2005; **48**: 159–66.
6. Vasudevan PC, Quarrell WJO. Prader–Willi and Klinefelter syndrome: a coincidence or not? *Clinical Dysmorphology* 2007; **16**: 127–29.
7. Liehr T, Mrasek K, Starke H, Claussen U, Schreiber G. Unusual small supernumerary marker chromosome (sSMC) 9 in a Klinefelter patient. *Cytogenetic and Genome Research* 2005; **111**: 179–81.
8. Manea SR, Gershin IF, Babu A, Willner JP, Desnick RJ, Cotter PD. Mosaicism for a small supernumerary ring X chromosome in a dysmorphic, growth-retarded male: mos47,XXY/48,XXY, +r(X). *Clinical Genetics* 1997; **52**: 432–5 .
9. Starke H, Seidel J, Henn W, Reichardt S, Volleth M, Stumm M et al. Homologous sequences at human chromosome 9 bands p12 and q13-21.1 are involved in different patterns of pericentric rearrangements. *European Journal of Human Genetics* 2002; **10**: 790–800.
10. Bouhjar IBA, Hannachi H, Zerelli SM, Labalme A, Gmidene A, Soyah N et al. Array-CGH study of partial trisomy 9p without mental retardation. *American Journal of Medical Genetics Part A* 2011; **155**: 1735–9.