

Obstruction of the Duodenum by a Preduodenal Portal Vein in *Situs Inversus*

ND Duncan¹, H Trotman³, M Seepersaud¹, SE Dundas², M Thame³, M Antoine³

ABSTRACT

Mirror image transposition of abdominal and thoracic viscera is termed situs inversus. Duodenal obstruction in situs inversus is rare. A preduodenal portal vein, though not uncommon in situs inversus, rarely causes duodenal obstruction. Where obstruction by a preduodenal portal vein is diagnosed, a duodeno-duodenostomy is the recommended treatment. A duodenal diaphragm and other more common causes of duodenal obstruction should also be excluded in these patients.

Obstrucción del Duodeno por una Vena porta Preduodenal en *Situs Inversus*

ND Duncan¹, H Trotman³, M Seepersaud¹, SE Dundas², M Thame³, M Antoine³

RESUMEN

La posición invertida de las vísceras torácicas y abdominales a modo de imagen de espejo se denomina situs inversus. La obstrucción del duodeno en situs inversus es rara. Una vena porta preduodenal, aunque no es inusual en situs inversus, raramente causa obstrucción duodenal. Cuando se diagnostica una obstrucción por una vena porta preduodenal, la duodenostomía es el tratamiento recomendado. Un diafragma duodenal y otras causas más comunes de la obstrucción duodenal, deben también excluirse en estos pacientes.

West Indian Med J 2007; 56 (3): 285

INTRODUCTION

Mirror image transposition of abdominal and thoracic viscera is termed *situs inversus* (1, 2). Total *situs inversus* affects both chest and abdomen while partial *situs inversus* affects one region only or both regions in an incomplete manner (2). *Situs inversus* is detectable in 1/4000 to 1/20,000 live births (2). Patients are susceptible to life threatening defects of the heart and abdomen, including cardiac chamber defects, transposition of the great vessels, intestinal malrotation, bowel and biliary atresias and splenic anomalies (3, 4).

Congenital obstruction of the duodenum is rare in *situs inversus*. Nawaz *et al* traced only 18 cases in the medical literature prior to 2004 (5). That study pointed to annular pancreas or a duodenal diaphragm causing obstruction in the majority of patients. Approximately 40% of *situs inversus* cases subjected to laparotomy have a preduodenal portal vein (PDPV) but this vein almost never causes obstruction (3, 6).

From: Department of Surgery, Radiology, Anaesthesia and Intensive Care¹, and Department of Obstetrics, Gynaecology and Child Health³, The University of the West Indies, Kingston 7, and Bustamante Hospital for Children², Arthur Wint Drive, Kingston 5, Jamaica.

Correspondence: Dr ND Duncan, Department of Surgery, Radiology, Anaesthesia and Intensive Care, The University of the West Indies, Kingston 7, Jamaica, West Indies. Fax: (876) 970-4302, E-mail: surradic@uwimona.edu.jm.

We herein report a case of duodenal obstruction in *situs inversus* caused by a PDPV.

CASE REPORT

A three-day old full term female baby presented with bilious vomiting from birth. The infant weighed three kilograms, was moderately dehydrated and had a non-distended abdomen. Babygram X-rays done on admission showed a reverse double bubble gas pattern (gastric bubble on the right and duodenal bubble on the left) and dextrocardia (Fig. 1). These features, along with limited intestinal gas, suggested incomplete duodenal obstruction and total *situs inversus*. Echocardiography confirmed dextrocardia in a heart that was otherwise normal. After correction of dehydration and hyponatraemia (sodium-124 mmol/L), laparotomy was performed through a left upper abdominal transverse incision. The duodenum, biliary tree and caecum were found to be situated in the left abdomen and the descending and sigmoid colon in the right.

The duodenal C-loop was incompletely formed and tethered by adhesive bands (Ladd's bands) in keeping with intestinal malrotation. The junction between the first and second part of the duodenum was compressed by a PDPV, causing proximal dilatation and distal collapse (Fig. 2). The adhesive duodenal bands were divided and an appendectomy done. Duodenotomy revealed no luminal obstruction. The

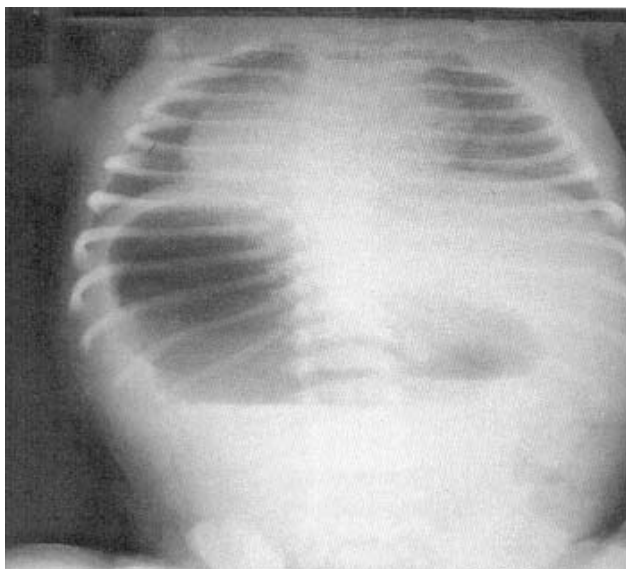


Fig. 1: Babygram showing reverse double bubble and dextrocardia.

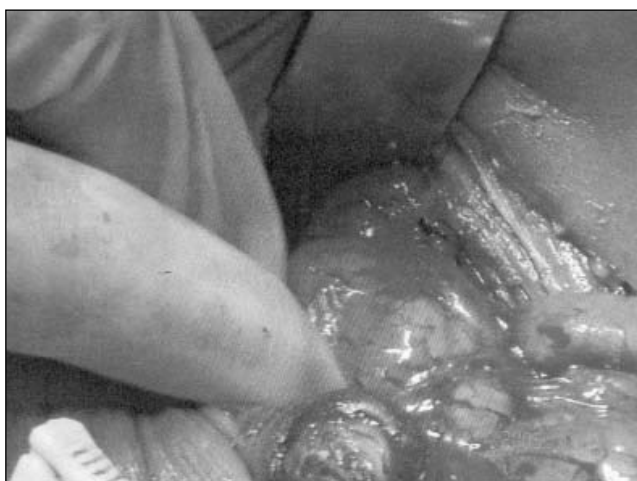

Fig. 2: Preduodenal portal vein compressing duodenum.

obstructing PDPV was bypassed by constructing a side-to-side duodeno-duodenostomy between dilated and collapsed duodenum.

Postoperatively, the baby had tonic clonic seizures presumed to be due to hyponatraemia (125 mmol/L) and hypocalcaemia (1.50 mmol/L). This was controlled by phenobarbitone and normal saline infusion. Duodenal paresis caused a delay in the commencement of feeds until day 12 post-surgery but subsequent recovery was uneventful leading to discharge on day 18.

DISCUSSION

Aristotle first detected *situs inversus* in animals and considered it a visitation from the gods (2–4). Fabricius uncovered the condition in cadavers in 1600 (1, 2) but the clinical significance of *situs inversus* was not grasped until the advent of

X-ray imaging which made diagnosis in humans easy and reliable (1, 2). Clinical syndromes with a definite link to *situs inversus* have been defined. These include asplenia (predominance of right sided structures) and polysplenia (predominance of left sided structures) syndromes (Ivemark's syndrome) (3), multiple organ malrotation (MOMS) syndrome (levoverision of liver, dextroversion of stomach and normal large and small intestines) (7) and Kartegener's syndrome (total *situs inversus*, bronchiectasis and chronic sinusitis) (3). All but the last are frequently associated with life-threatening intra- abdominal and cardio-pulmonary anomalies (3, 4, 7).

A PDPV rarely causes duodenal obstruction (6, 8, 9). It derives from a caudal anastomotic vein connecting the two vitelline veins at the 5 mm embryo stage. Non-regression of this vein leads to a ventrally routed portal vein (8). Surgeons should anticipate a PDPV in *situs inversus* and ascertain its presence by ultrasonography, computed tomography (CT) or magnetic resonance imaging (MRI) (3, 6). Steps should be taken to avoid injury to this vein because of possible life-threatening consequences (8). Duodenal obstruction by a PDPV is best treated by an intestinal bypass procedure such as a duodeno-duodenostomy (6, 8, 9).

The main causes of duodenal obstruction in *situs inversus* were found to be annular pancreas, duodenal webs, adhesive bands and midgut volvulus (3). This case had both a PDPV and duodenal adhesive bands linked to intestinal malrotation. The PDPV was diagnosed as the source of duodenal obstruction because the vessel crossed the duodenum at an anatomical transition point between proximally dilated and distally collapsed duodenum. Furthermore, no intraluminal obstruction was detected after duodenotomy and passage of a catheter into the distal duodenum (3, 10).

Where intestinal malrotation is found at laparotomy, a modified Ladd's procedure (lysis of duodenal adhesions and appendectomy) should be performed (3, 5, 10) to reduce the risk of future adhesive obstruction and acute appendicitis. The latter is difficult to diagnose in *situs inversus*. One study reported false pain projection to the right in 33% of such patients with appendicitis (2). This false pain projection along with confounding symptomatology leads to misdiagnosis and wrongly placed incisions (2, 3).

The potential for cardiac pathology is so great in *situs inversus* and the consequences so unpredictable that all surgical cases should be subjected to echocardiography prior to anaesthesia (5).

REFERENCES

1. Wood GO, Blalock A. Situs inverse totalis and disease of the biliary tract: survey of the literature and report of a case. *Arch Surg* 1940; **40**: 885–96.
2. Blegen HM. Surgery in situs inversus. *Ann Surg* 1949; **129**: 244–59.
3. Ruben GD, Templeton JM, Ziegler MM. Situs inversus: the complex inducing neonatal intestinal obstruction. *J Pediatr Surg* 1983; **18**: 751–6.
4. Fonkalsrud EW. Abdominal manifestations of situs inversus in infants and children. *Arch Surg* 1966; **92**: 791–5.

5. Nawaz A, Matta H, Hamchou M, Jacobez A, Trad O, Al Salem AH. Situs inversus abdominis in association with congenital duodenal obstruction: a report of two cases and review of the literature. *Pediatr Surg Int* 2005; **21**: 589–92.
6. Mordehai J, Cohen Z, Kurzbart E, Mares AJ. Preduodenal portal vein causing duodenal obstruction associated with situs inversus, intestinal obstruction and polysplenia: a case report . *J Pediatr Surg* 2002; **37**: E5.
7. Adeyemi SD. Combination of annular pancreas and partial situs inversus: a multiple organ malrotation syndrome associated with duodenal obstruction. *J Pediatr Surg* 1988; **23**: 188–91.
8. Boles ET, Smith B. Preduodenal portal vein. *Pediatrics* 1961; **28**: 805–9.
9. Fernandes ET, Burton EM, Hixson SD, Hollabaugh RS. Preduodenal portal vein: surgery and radiographic appearance. *J Pediatr Surg* 1990; **25**: 1270–2.
10. Budhiraja S, Singh G, Miglani HPS, Mitra SK. Neonatal intestinal obstruction with isolated levocardia. *J Pediatr Surg* 2000; **35**: 1115–6.