

Ocular Angiostrongyliasis – First Case Report from Jamaica

A Mattis¹, L Mowatt², A Lue¹, J Lindo², H Vaughan²

ABSTRACT

A 30-year old female presented with a one-month history of blurred vision in her left eye. Examination revealed a live motile worm in the anterior chamber of the left eye. She also had retinal pigment epithelial disturbance with focal intraretinal haemorrhage. The 19.9 mm worm was surgically removed and identified as Angiostrongylus cantonesis. She was treated with oral mebendazole. Her vision improved from counting fingers in the left eye to 6/36. This is the first documented case of ocular angiostrongyliasis in Jamaica.

La Angiostrongyliasis Ocular – Primer Caso Reportado en Jamaica

A Mattis¹, L Mowatt², A Lue¹, J Lindo², H Vaughan²

RESUMEN

Una mujer de 30 años se presentó con una historia de visión borrosa en el ojo izquierdo por un mes. El examen reveló la presencia de un gusano móvil vivo en la cámara anterior de su ojo izquierdo. También presentaba una alteración del epitelio pigmentario de la retina con hemorragia intraretiniana focal. El gusano de 19.9 mm fue extraído quirúrgicamente e identificado como Angiostrongylus cantonesis. La paciente fue tratada con mebendazole oral. Su visión mejoró – pasando de poder contar sólo sus dedos con el ojo izquierdo a una visión de 6/36. Se trata del primer caso de angiostrongyliasis ocular documentado en Jamaica.

West Indian Med J 2009; 58 (4): 383

INTRODUCTION

Angiostrongylus cantonesis, a nematode whose definitive host is the rodent, was first described by Chen in 1935. Humans are infected by ingestion of molluscan, intermediate host or paratenic hosts such as crabs, shrimps and vegetables or fruits contaminated by larvae. This zoonosis characteristically causes eosinophilic meningoencephalitis. We present a case report of the first documented case of ocular angiostrongyliasis in Jamaica.

CASE REPORT

A 30-year old female was seen in the Eye Clinic at the Kingston Public Hospital, Jamaica, complaining of blurred vision in her left eye for one-month duration. She had been treated at her local health centre with chloramphenicol eye drops with no improvement. She had no recent history of headache, neck stiffness, fever or vomiting.

Her visual acuities were 6/5 and counting fingers in her right and left eyes, respectively. On examination using slit lamp biomicroscopy, a live worm was seen moving freely in the anterior chamber of her left eye. The cornea was clear and the anterior chamber was quiet with no cells or flare. Fundus examination of the left eye revealed intraretinal haemorrhages and loss of the foveal light reflex. The retina was flat. Her right eye was normal.

Investigations included a complete blood count and stool for ova and cysts. Her haemoglobin was borderline for anaemia (Hb 11.6 mg/dL); white blood cell count was $2.7 \times 10^9/L$ but there was no eosinophilia. Stool was negative for ova and cysts.

The patient underwent surgical removal of the worm under local anaesthesia (peribulbar). An infero-temporal clear cornea incision was made and viscoelastic used to manually extract the worm. The worm was recovered alive and sent for microbiological analysis.

Postoperatively, the patient was commenced on topical steroid and antibiotic eye drops. Visual acuity had improved to 6/60 in her left eye on day one postoperatively. At six weeks postoperatively, her visual acuity had improved to 6/36 in that eye.

From: ¹Kingston Public Hospital, North Street, Kingston, Jamaica, West Indies, and ²The University Hospital of the West Indies, Kingston 7, Jamaica, West Indies.

Correspondence: Dr L Mowatt, Department of Surgery, Radiology, Anaesthesia, and Intensive Care, The University of the West Indies, Kingston 7, Jamaica, West Indies. Fax: (876) 927-1270, e-mail: lizettemowatt@yahoo.com

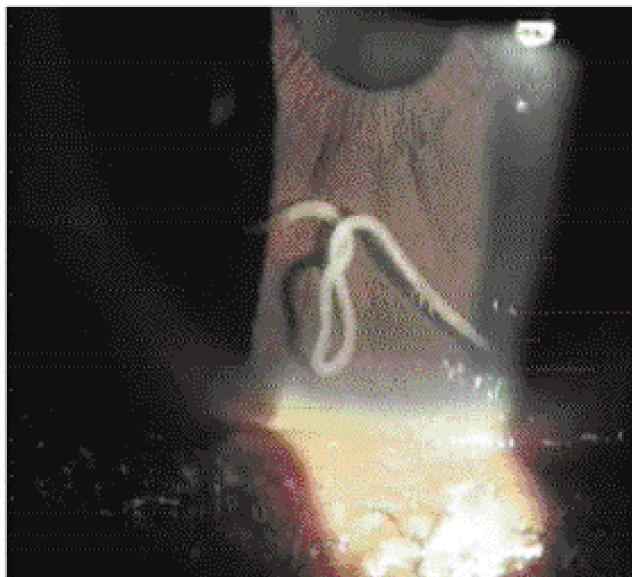


Figure: Male adult *Angiostrongylus cantonensis* in the anterior chamber of the left eye.

The worm was identified as a young adult male *A. cantonensis* based on morphometrics. It was 19.9 mm in length. The patient was treated with mebendazole and investigated for systemic involvement but this was not confirmed.

DISCUSSION

A. cantonensis (lung worm of rats) is a parasite of rats, with snail and slug intermediate hosts and paratenic hosts which include shrimps, crabs, frogs and toads. *A. cantonensis* used to be endemic mainly in Southeast Asia and the Pacific basin; however, in recent years, it has been found in New Orleans, Cuba, Puerto Rico, the Bahamas, the Dominican Republic and Jamaica (1–7). The infection is usually acquired from eating raw snails or slugs, undercooked infected paratenic hosts or vegetables contaminated by snails and slugs.

The index patient worked in an orange orchard. It is postulated that she might have acquired this infestation by ingestion of contaminated fruits or vegetables or direct entry of the larvae into the bloodstream through broken skin.

Typically, there is an incubation period of 2–8 weeks where third stage larvae from the host tissue penetrate the intestinal tissues of humans and are carried haematogenously to the liver, lungs and central nervous system often resulting in eosinophilic meningitis (8).

Intraocular angiostrongyliasis is a rare condition seen in 1.1% of cases of angiostrongyliasis with 0.8% of infected cases presenting only with ocular symptoms (8). The most common symptom is blurred vision, but they may have an iritis, keratitis, and episcleritis in the anterior segment (9, 10). Posterior segment findings include local or generalized disturbance of the retinal pigment epithelium, optic neuritis and papilloedema (8, 11–13).

The worm is most commonly found intravitreal but may be located subretinal (usually posterior pole) or in the anterior chamber (8, 9, 11–15). Usually a single adult worm is present. Patikulsila *et al*, reported two worms intravitreal (only one still motile). There was no ocular dominance of the affected eye or gender of the worm. Most worms were between 9.8 – 11.4 mm in size (8, 16). The motile worm in the anterior segment in this case was larger than those found in previously reported cases.

The visual acuity appears to be permanently affected in patients with subretinal located nematodes or retinal pigment epithelial changes. However, if the worm is found in the anterior segment, removal of the nematodes usually results in improvement of the vision (8, 11, 12). This was the experience in the present case where the patient had intraretinal haemorrhages and retinal pigment epithelial macular changes which would have resulted in the reduction of vision, which, even though it improved after removal of the worm did not return to normal. The worm may have migrated from the posterior segment into the anterior segment resulting in the posterior segment findings. The pigmentary changes may be due to actual mechanical subretinal migration or inflammation of the choroid and retina, with the intraretinal haemorrhages associated with its entrance into the vitreal cavity.

Anthelmintics (such as thiabendazole, mebendazole, levamisole, pyrantel, flubendazole) have been used to treat the CNS infections, however, the drug's bioavailability or effectivity level in the vitreous and aqueous areas is unknown (17 – 19). The use of anthelmintic agents alone in meningitis is controversial because of the potential harmful effect of the antigen released after death of the nematodes. In Wang L *et al*, larvicidal drugs and steroids were used with good effect on the patient with optic neuritis; however, the steroids may have dampened the inflammation and the effectivity of the combined treatment has been shown recently for albendazole and prednisolone (3). Topical and oral steroids alone have been used with good effect after removal of the worm (8, 20).

In most reports, the worm was removed or ablated with laser except in Nelson *et al* (1982) and Scrimgeour *et al*, (9, 12) where the patient recovered on topical steroids and antibiotics; however, the serology showed elevated titers but the patient defaulted follow-up. Diode and YAG laser have been used to kill adult worms in the anterior and subretinal areas, respectively, prior to removal (8). Intravitreal worms may be immobilized by an intravitreal cryoprobe and removed with a foreign body forceps (13). However, the visual outcome depends on the initial visual defect (8).

This is the first reported case of intraocular angiostrongyliasis in Jamaica. The worm may be recovered from the eye in 0.3% of cases and may be associated with an eosinophilic meningitis in 0.8% of infections (8). Ophthalmologists and physicians must be alert to this possibility and a dilated eye examination should be performed on all patients

with meningitis with eosinophilia, and who present with blurred vision as the adult worm may be located in the posterior segment of the eye.

REFERENCES

1. Kliks MM, Palumbo NE. Eosinophilic meningitis beyond the Pacific Basin: the global dispersal of a peridomestic zoonosis caused by *Angiostrongylus cantonensis*, the nematode lungworm of rats. *Soc Sci Med* 1992; **34**: 199–12.
2. Campbell BG, Little MD. The finding of *Angiostrongylus cantonensis* in rats in New Orleans. *Am J Trop Med Hyg* 1988; **38**: 568–73.
3. Aguiar PH, Morera J, Pascual J. First record of *Angiostrongylus cantonensis* in Cuba. *Am J Trop Med Hyg* 1981; **30**: 963–5.
4. Andersen E, Gubler DJ, Sorenson K, Beddard J, Ash LR. First report of *Angiostrongylus cantonensis* in Puerto Rico. *Am J Trop Med Hyg* 1986; **35**: 319–22.
5. Vargas M, Gomez Perez JD, Malek EA. First record of *Angiostrongylus cantonensis* (Chen, 1935) Nematoda: Metastrongylidae in the Dominican Republic. *Trop Med Parasitol* 1992; **43**: 253–5.
6. Barrow KO, Rose A, Lindo JF. Eosinophilic meningitis: is *Angiostrongylus cantonensis* endemic in Jamaica? *West Indian Med J* 1996; **45**: 70–1.
7. Lindo JF, Waugh C, Hall J, Cunningham-Myrie C, Ashley D, Eberhard ML et al. Enzootic *Angiostrongylus cantonensis* in rats and snails after an outbreak of human eosinophilic meningitis in Jamaica. *Emerg Infect Dis* 2002; **8**: 324–6.
8. Sawanyawisuth K, Kitthaweesin K, Limpawattana P, Intapan PM, Tiamkao S, Jitpimolmard S et al. Intraocular angiostrongyliasis: clinical findings, treatments and outcomes. *Trans R Soc Trop Med Hyg* 2007; **101**: 497–501.
9. Scrimgeour EM, Chambers BR, Kaven J. A probable case of ocular angiostrongyliasis in New Britain, Papua New Guinea. *Trans R Soc Trop Med Hyg* 1982; **76**: 538–40.
10. Wang LC, Wang IH, Jou JR. Optic neuritis secondary to angiostrongylus cantonensis infection. *Ocul Immunol Inflamm* 2006; **14**: 189–91.
11. Malhotra S, Mehta D, Arora R, Chauhan D, Ray S, Jain M et al. Ocular angiostrongyliasis in a Child- First Case Report from India. *J Trop Pediatr* 2005; **26**.
12. Nelson RG, Warren RC, Scotti FA, Call TG, Kim BS. Ocular angiostrongyliasis in Japan: a case report. *Am J Trop Med Hyg* 1988; **38**: 130–2.
13. Patikulsila D, Ittipunkul N, Theerakittikul B. Intravitreal angiostrongyliasis: report of 2 cases. *J Med Assoc Thai* 2003; **86**: 981–5.
14. Singalavanija A, Wangspa S, Teschareon S. Intravitreal angiostrongyliasis. *Aust N Z J Ophthalmol* 1986; **14**: 381–4.
15. Kumar V, Kyprianou I, Keenan JM. Ocular angiostrongyliasis: removal of a live nematode from the anterior chamber. *Eye* 2005; **19**: 229–30.
16. Widago, Sunardi, Lokollo DM, Margono. SS Ocular angiostrongyliasis in Semarang, Central Java. *Am. J Trop Med Hyg* 1977; **26**: 72–4.
17. Tsai HC, Liu YC, Kunin CM, Lee SS, Chen YS, Wann SR et al. Eosinophilic meningitis caused by *Angiostrongylus cantonensis*: report of 17 cases. *Am J Med* 2001; **111**: 109–14.
18. Mentz MB, Graeff-Teixeira C. Drug Trials for treatment of human angiostrongyliasis. *Rev Inst Med Trop Sao Paulo* 2003; **45**: 179–84.
19. Lindo JF, Escoffery CT, Reid B, Codrington G, Cunningham-Myrie C, Eberhard ML. Fatal autochthonous eosinophilic meningitis in a Jamaican child caused by *Angiostrongylus cantonensis*. *Am J Trop Med Hyg* 2004; **70**: 425–8.
20. Chotmongkol V, Sawadpanitch K, Sawanyawisuth K, Louhawilai S, Limpawattana P. Treatment of eosinophilic meningitis with a combination of prednisolone and mebendazole. *Am J Trop Med Hyg* 2006; **74**: 1122–4.