

## Spontaneous Resorption of Exudative Retinal Detachments Associated with Ischaemic Central Retinal Vein Occlusion

L Mowatt<sup>1</sup>, A Tyagi<sup>2</sup>

### INTRODUCTION

Exudative retinal detachments occur as a result of fluid flow alterations and breakdown of the blood retinal barrier which is seen in inflammatory, infectious and neoplastic disease states in addition to abnormal vasculature. Ischaemic central retinal vein occlusion (CRVO) is uncommonly associated with exudative detachments (1, 2). We report a case of exudative retinal detachments secondary to ischaemic CRVO which resolved with conservative management.

### Case Report

A 64-year old hypertensive male was referred to hospital for a shallow left retinal detachment. He had a history of bilateral ischaemic CRVO sequentially in his right and left eye in 2001 and 2002 respectively and was known to have hypercholesterolaemia, hypertension, angina, cardiac arrhythmias and was a chronic smoker. He had undergone multiple sessions of panretinal photocoagulation bilaterally for neovascularization.

His visual acuity was 6/36 and 6/18 in the right and left eyes respectively when he presented with the exudative retinal detachment. He also had mild nuclear sclerosis and macular ischaemia bilaterally. There was no associated traction, retinal tears, holes or degeneration associated with this detachment. He had no signs of ocular inflammation. The detachment occurred in an area that had previously being lasered (Fig. 1).

He was managed conservatively. Two months post presentation, a new non-communicating exudative detachment developed in the inferior temporal retina just outside the temporal arcades. However, his vision remained unchanged as the macula was not involved in this detachment and he had well-developed collateral vessels (Fig. 2). The exudative detachments spontaneously resolved five months after presentation.

### DISCUSSION

Exudative retinal detachment complicates 0.6% of all retinal vascular occlusions [central, hemispheric and branch] (1–3). The detachments are usually located in the posterior pole and are associated with marked retinal oedema. Collateral de-

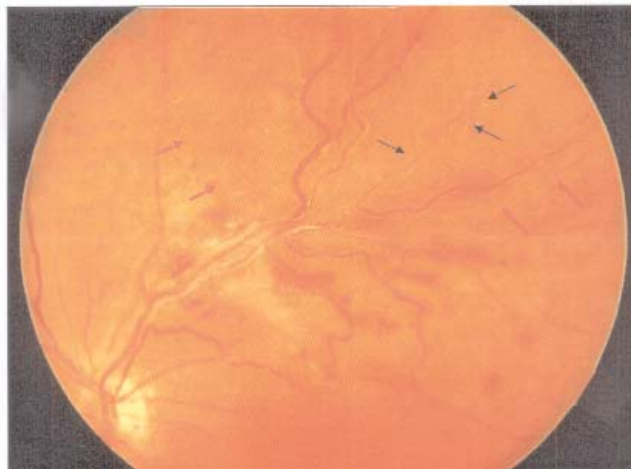


Fig. 1: Black arrows indicate multiple laser burns within elevated retina. Red arrows indicate the edge of the exudative detachment. Note the associated resolving retinal haemorrhages and arteriosclerotic vessels.

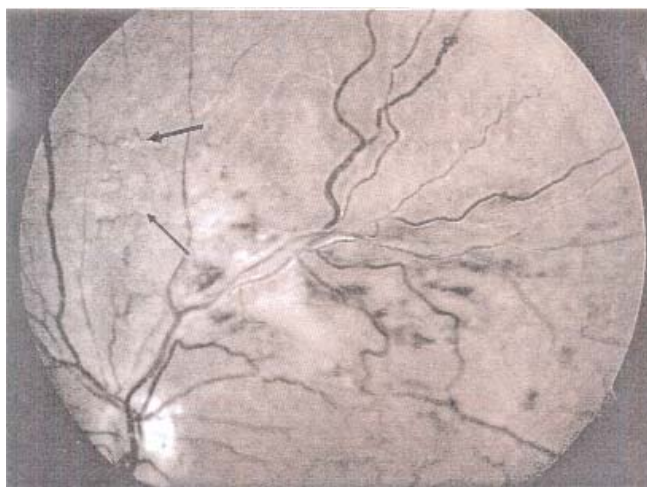

Fig. 2: Red free photograph showing collateral circulation indicated by black arrows.

velopment has been noted and these may occur at the optic disc or intraretinal; their absence has been implicated in persistent exudation (2, 3). Exudative retinal detachment has been noted to be more common in CRVO affecting the younger age group (average age 25 years) characteristically presenting with associated oedema and haemorrhage in the macular area (4).

The fluid movement across the retinal pigment epithelium (RPE) due to active transport, oncotic forces and hydrostatic pressure maintains the attachment to the

From: <sup>1</sup>Department of Surgery, Radiology, Anaesthesia, and Intensive Care, The University of the West Indies, Kingston 7, Jamaica; <sup>2</sup>Sandwell and West Birmingham NHS Trust, Birmingham and Midland Eye Center, Birmingham, B18 7QH, England.

Correspondence: Dr L Mowatt, Department of Surgery, Radiology, Anaesthesia and Intensive Care, The University of the West Indies, Kingston 7. Fax: (876) 702-4432, E-mail: lizettemowatt@yahoo.com

neurosensory retina. Breakdown of these mechanisms from inflammation can result in exudative retinal detachments.

Weinberg *et al* reported five cases of exudative retinal detachment associated with CRVO, four of the five were treated with laser and resolved; however, all five cases had poor visual outcomes. Savant *et al* recently reported poor visual outcomes despite photocoagulation for exudative detachments following CRVO. This may occur due to neovascular glaucoma in 40–56% of cases, which signifies the presence of significant ischaemia (3, 4).

Laser treatment assists in resolution of retinal oedema due to the loss of the mechanical barrier produced by intact RPE which allows the oncotic forces of the choriocapillaries to diminish pre-existing subretinal fluid (5).

The index case had multiple risk factors for central retinal vein occlusion and compromised retinal circulation. It demonstrates that exudative detachments associated with

vascular leakage due to ischaemic damage can spontaneously resolve with good result. This may be associated with the improved vascular flow from collateral circulation.

#### REFERENCES

1. Savant W, Dwarika D, Scott RAH, Stavrou P. Exudative retinal detachment following central retinal vein occlusion. *Eye* 2004; **18**: 224–6
2. Weinberg D, Jampol LM, Schatz H Brady KD. Exudative detachments following central and hemicentral retinal vein occlusions. *Arch Ophthalmol* 1990; **108**: 271–5
3. Ravalico G, Battaglia Parodi M. Exudative retinal detachment subsequent to retinal vein occlusion. *Ophthalmologica* 1992; **205**: 77–82.
4. Peng XY, Wang JZ, Li ZH, Chen JT. Clinical features of central retinal vein occlusion complicating exudative retinal detachment. *Zhonghua Yan Ke Za Zhi* 2006; **42**: 492–5.
5. Negi A, Marmor MF. Experimental serous retinal detachment and focal pigment epithelial damage. *Arch Ophthalmol* 1984; **102**: 445–9.