

Isoniazid-resistant Disseminated *Mycobacterium Tuberculosis* in a Jamaican Infant with HIV/AIDS

I Singh-Minott^{1,2}, RB Pierre^{1,2}, O Olugbuyi^{1,2}, J Dunkley-Thompson¹, D Haughton³, CDC Christie^{1,2}

ABSTRACT

A case report of isoniazid-resistant disseminated tuberculosis in a young child perinatally co-infected with human immunodeficiency virus (HIV-1) and the challenges managing this child in a resource-constrained setting.

Mycobacterium Tuberculosis Diseminada Resistente a Isoniacida en Infantes Jamaicanos con VIH/SIDA

I Singh-Minott^{1,2}, RB Pierre^{1,2}, O Olugbuyi^{1,2}, J Dunkley-Thompson¹, D Haughton³, CDC Christie^{1,2}

RESUMEN

Un reporte de caso de tuberculosis diseminada resistente a isoniacida en un niño co-infectado perinatalmente con el virus humana de la inmunodeficiencia (VIH-1) y los desafíos para tratar a este niño en un contexto con recursos restringidos.

INTRODUCTION

Mycobacterium tuberculosis (TB) is one of the leading annual causes of mortality in children co-infected with the human immunodeficiency virus (HIV-1) worldwide (1). Individuals with HIV-1 infection are more susceptible to *M tuberculosis* since CD4⁺ T-cells play an important role in inhibiting intracellular growth of mycobacteria. Hence HIV-infected individuals co-infected with TB tend to progress more rapidly to TB disease compared to non-HIV-infected individuals (2).

Worldwide, an estimated 8.8 million new cases of TB occur annually (1) and children less than 15-years old account for 10.7% of infections (3). In Jamaica, there were 196 new cases of TB in 2005 with an incidence of 7.0/100 000 population (1). In 2004, Geoghagen *et al* reported on TB disease in Jamaican children admitted to the University Hospital of the West Indies, 46% (n = 24) of whom were co-infected with HIV-1 (4).

Diagnosis of TB in children is challenging due to the lack of standardized reliable case definitions (4, 5). Up to 50% of children may have both a negative smear for acid fast bacilli (AFB) and a negative culture despite the presence of active disease (6, 7).

Currently in Jamaica, the challenge is even greater due to limited laboratory capacity for *M tuberculosis* culture and sensitivity. Patients are treated empirically presuming that isolates are sensitive to standard first line anti-TB drugs.

Globally, TB control has been threatened by emergence of multi-drug-resistant tuberculosis (MDR-TB) defined as strains of *M tuberculosis* resistant to at least isoniazid and rifampicin. The occurrence of MDR-TB is estimated to be > 4% in the developing world (8). Isoniazid-resistant TB incidence is unknown in Jamaica.

This report documents the first case of disseminated isoniazid-resistant TB in a young child co-infected with HIV against the local background of limited laboratory capacity for isolate identification and drug susceptibility testing.

CASE REPORT

The index case is a 16-month old male child born to an 18-year old primigravida who was diagnosed with HIV infection in the second trimester. She did not receive antiretroviral

From: ¹Department of Obstetrics, Gynaecology and Paediatrics, The University of the West Indies, ²The University Hospital of the West Indies, Kingston 7 and ³May Pen Hospital, Jamaica.

Correspondence: Professor CDC Christie, Department of Obstetrics, Gynaecology and Paediatrics, The University of the West Indies, Kingston 7, Jamaica, West Indies. E-mail: celia.christiesamuels@uwimona.edu.jm.

therapy or chemoprophylaxis in the antenatal period or during labour. The mother did not disclose her HIV seropositive status to the staff in the labour ward. The infant was born at term *via* spontaneous vaginal delivery, birthweight 3.17 kgs and received single dose nevirapine at birth. Replacement feeds were provided and the infant subsequently commenced co-trimoxazole for *Pneumocystis jirovecii* (PCP) prophylaxis. The Bacille Calmette Guérin (BCG) vaccine was administered at birth.

At six months of age, he was evaluated in the outpatient department and noted to have oral candidiasis, bronchiolitis and generalized hypertonia. He was admitted to a type B hospital (*ie* there are no subspecialties available, only medicine, general surgery, obstetrics and gynaecology, and paediatrics) at eight-months old with persistent oropharyngeal candidiasis, bronchopneumonia and gastroenteritis. Re-admission occurred at nine months of age for persistent vomiting and malnutrition. At this time, he was diagnosed with severe HIV/AIDS with CDC category C disease associated with HIV encephalopathy, spastic quadriplegia and global developmental delay. Highly active antiretroviral therapy (HAART) was commenced with zidovudine, lamivudine and nevirapine. HIV-PCR screening test was not yet introduced to Jamaica.

In the two months following initiation of HAART, the infant had four admissions because of recurrent fever, respiratory distress and failure to thrive. He was treated presumptively for PCP pneumonia and acute bacterial infections. Five months after commencing HAART (13 months old), he was re-admitted with recurrent fever and persistent respiratory distress. On examination, he had failure to thrive, generalized lymphadenopathy, hepatosplenomegaly and right axillary adenitis involving the ipsilateral site of the BCG vaccination.

He was subsequently referred to the University Hospital of the West Indies for further management. The chest radiograph showed a widened mediastinum and the mantoux skin test was negative. Pulmonary TB was confirmed when acid fast bacilli were identified in gastric washings.

First-line quadruple anti-tuberculous (anti-TB) therapy was commenced with rifampicin (RIF), isoniazid (INH), ethambutol (ETH) and pyrazinamide (PZA). Recurrent painful erythematous subcutaneous nodules first presented on the lower limbs but progressed to involve upper limbs and scalp and subsequently drained serosanguinous fluid (Fig. 1). Excision biopsy of the nodules and right axillary lymph node revealed caseating granulomas on histology (Figs. 2, 3). Despite appropriate first line anti-TB therapy with direct observational therapy in hospital and antibiotic coverage for possible bacterial superinfections, he continued to have intermittent pyrexia. The plasma HIV RNA (viral load) assessed five months after HAART initiation was 13 300 copies/ml and the CD4⁺ was 44%.

Three months after initiating anti-TB therapy, the regional laboratory at the Caribbean Epidemiology Centre

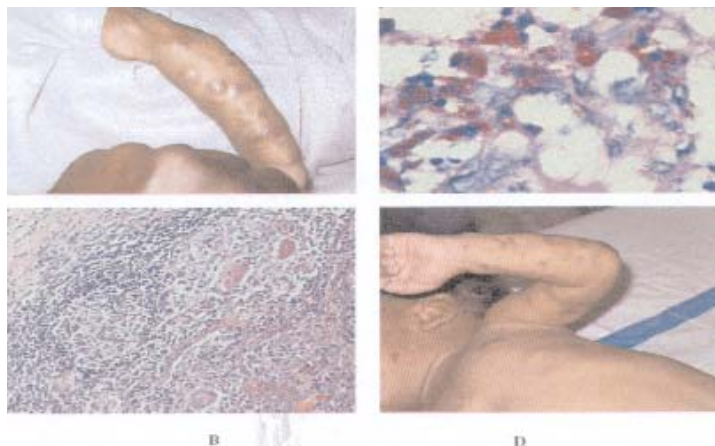


Figure: Subcutaneous nodules (tuberculosis cutis) prior to treatment seen in A; B shows tuberculous granulomas, chronic inflammatory cells (histiocytes and lymphocytes); C shows sheets of acid fast bacilli within the tuberculous granulomas; D shows the complete resolution of the subcutaneous nodules with resultant scarring after eight months on second line anti-tuberculous therapy.

(CAREC) reported isolating *M tuberculosis* from the gastric washings, subcutaneous nodules (*tuberculosis cutis*) and the axillary lymph node. The isolate was reported as resistant to isoniazid but susceptible to rifampicin, ethambutol and streptomycin. Sensitivity testing was not reported for pyrazinamide.

In consultation with the Infectious Diseases team, isoniazid was discontinued and the anti-TB regimen revised to include RIF, ETH, PZA with the addition of streptomycin (given intramuscularly) and a fluoroquinolone (ciprofloxacin). Evaluation for other target sites of dissemination (liver, lung, bone, brain, eyes and kidney) was non-contributory.

Public health officials were emergently advised to initiate surveillance for the source of drug-resistant TB infection and to identify any potential contacts.

Contact tracing including mantoux testing was conducted on family members but were reported negative. The probable adult source for this child's infection has not yet been identified. In addition, all possible in-hospital contacts were screened by mantoux testing and chest radiographs, as indicated. Six months following initiation of the revised anti-TB regime, the young child demonstrated significant weight gain, resolution of cutaneous lesions [*tuberculosis cutis*] (Fig. 4) and his repeat gastric washings were negative for acid fast bacilli and the culture showed no growth.

DISCUSSION

Tuberculosis is a leading cause of death amongst HIV-infected individuals worldwide and accounted for 250 000 deaths in 2004 in TB-HIV co-infected populations (9). The emergence of drug-resistant TB has increasingly become a global problem and a threat to TB control (10). This case highlights the challenges faced in diagnosing and managing TB in resource-constrained settings.

Limited laboratory capacity in Jamaica for diagnosis and susceptibility testing for *M tuberculosis* was a significant barrier to initiating timely specific interventions. The local TB laboratory only offers microscopy reports from direct smears only in the identification of acid fast bacilli. The TB laboratory is not equipped to identify the organism or offer drug susceptibility testing. Furthermore, regarding the clinical progression following HAART initiation, BCG vaccine-induced disease (11), *Mycobacterium bovis* co-infection, drug resistant TB, immune reconstitution syndrome (12, 13) and antiretroviral treatment failure were also considered in the differential diagnoses.

Commercial kits utilizing polymerase chain reaction for detection of *M tuberculosis* can detect the organism within two hours of testing but these are unavailable in Jamaica. And the recently available interferon-alpha release assays for diagnosis of TB in adults have not yet been validated for use in infants, children and adolescents or immunocompromised individuals (2).

The treatment of drug resistant TB in children is challenging. The second-line drugs are expensive, have an increased toxicity profile and some (*eg* streptomycin) require parenteral administration. Long-term use of aminoglycosides is associated with nephrotoxicity and ototoxicity (14). Fluoroquinolones are relatively contraindicated in the paediatric age group because of the risk for cartilage abnormalities observed in human testing (15). Although Burkhardt *et al* reviewed 7000 children between ages 5–24 years who received fluoroquinolones and observed no association between quinolone usage and arthropathy (16). Second-line anti-TB therapy also requires prolonged hospitalization, separation from parents, loss of school time and resultant psychosocial impact of institutionalization.

Data are limited regarding the optimal duration of therapy for drug resistant TB in HIV co-infected children (17–20). A retrospective review of 39 Peruvian children < 15 years of age with multidrug resistant TB demonstrated a 93% cure rate (21). Children were treated with a combination of first and second-line therapy for 18–24 months (for a minimum of twelve consecutive months of negative cultures). Just two of the 39 children were HIV-infected.

In-hospital infection control presented a challenge in this case. Drug resistant TB especially in HIV co-infected individuals requires stringent methods to control cross infection such as confinement to a negative pressure room and other special precautions for nursing. Without appropriate isolation facilities great concern was expressed regarding exposure to healthcare personnel, other patients and visitors to the ward. This child co-infected with HIV and resistant TB had pulmonary TB with disseminated actively draining skin lesions with the potential risk of transmission to contacts in the healthcare setting. Children with HIV and TB co-infection are more likely to transmit TB in the healthcare setting (22). Greater consideration needs to be given for including rooms with air at negative pressure for nursing these

patients in future hospital design. In addition, adult community contacts of the patient should be barred from visiting the hospital until they had been screened with a Mantoux skin test and chest radiograph and active tuberculosis had been conclusively excluded. Nosocomial TB needs to be considered and actively investigated at both hospitals where this child was cared for and treated. Of greater concern is the impact of exposure in the community from which this index case was referred and the fact that the probable adult source had not been identified. This case has highlighted the tardiness of contact tracing and that paediatric TB is dependent on prompt diagnosis and treatment of the adult contact as well as appropriate chemoprophylaxis of exposed infants and children.

Directly Observed Treatment Short-course (DOTS) therapy is the current programme used in the therapeutic management of TB in Jamaica. While adherence is assured in the hospital setting, access to and monitoring of continued anti-TB therapy following discharge from hospital are hampered by affordability and availability of the drugs and limited human resource. DOTS therapy constitutes the heart of the Stop TB Strategy (23) and the key components encompass political commitment and sustained financing case detection through quality-assured bacteriology standardized supervised treatment, an effective drug supply and monitoring, evaluation and impact assessment. These criteria challenge the framework of the current programme in Jamaica and raise significant implications for the promotion of multi-drug resistant TB in the setting.

There are critical ‘gaps’ in the pathway of activities leading to effective TB control in our setting. Inadequate numbers of trained personnel for surveillance, contact tracing, laboratory evaluation and monitoring of community-based treatment continue to hinder optimal management of probable cases of TB. Although policies are in place, effective dissemination of information and retraining of new healthcare personnel should be instituted. The deficiencies of laboratory capacity require urgent attention. Alternatively, expedient collaboration with CAREC could be explored in the interim. The Ministry of Health could consider accessing the National Health Fund to enable free access to anti-TB drugs and thus promote adherence while limiting the development of resistance.

Internationally, the World Health Organization (WHO) provides guidance on scaling-up TB control activities through the Global Plan to Stop TB 2006–2015 (23). With the aim to sustain high levels of case detection (at least 70%) and cure (85% treatment success), developing countries have the framework on which to effectively reduce the impact of TB among HIV co-infected populations. However, to achieve this will require political commitment, financial support, effective intervention, patients’ involvement, community participation and ongoing research (24) and development of improved drugs, diagnostics and vaccines.

In conclusion, the goal of managing drug-resistant TB should be focussed on primary prevention and effective treatment. In Jamaica, development of drug resistant TB can be reduced by ensuring appropriately prescribed anti-TB drug dosages, implementing an effective DOTS programme, providing free and amenable access to the drugs, implementing policies and programmes to prevent nosocomial infection and establishing effective monitoring systems. The newer rapid methods for detection of the organism and resistance patterns must be made accessible to developing countries where the burden of TB and HIV are greatest. Controlled trials on effective treatment protocols for HIV-infected children co-infected with tuberculosis are also needed.

REFERENCES

1. Global tuberculosis control: surveillance, planning, financing. WHO report 2007. Geneva, World Health Organization (WHO/HTM/TB/2007.376). Accessed September 3, 2007 at http://www.who.int/tb/publications/global_report/2007/pdf/full.pdf
2. Starke JR. Interferon- γ release assays for diagnosis of tuberculosis infection in children. *Pediatr Infect Dis J*. 2006; **25**: 941–2.
3. Corbett EL, Watt CJ, Walker N, Maher D, Williams BG, Raviglione MC et al. The growing burden of tuberculosis: global trends and interaction with HIV epidemic. *Arch Intern Med* 2003; **163**: 1009–21.
4. Geoghagen M, Farr JA, Hambleton I, Pierre R, Christie CD. Tuberculosis and HIV co-infections in Jamaican children. *West Indian Med J* 2004; **53**: 339–45.
5. Hesselning AC, Schaaf HS, Gie RP, Starke JR, Beyers N. A critical review of diagnostic approaches used in the diagnosis of childhood tuberculosis. *Int J Tuberc Lung Dis*. 2002; **6**: 1038–45.
6. de Charmace G, Delacourt C. Diagnostic techniques in paediatric tuberculosis. *Paediatr Respir Rev* 2001; **2**: 120–6.
7. Khan EA, Starke JR. Diagnosis of tuberculosis in children: increased need for better methods. *Emerg Infect Dis* 1995; **1**: 115–23.
8. World Health Organization. Anti-tuberculosis Drug Resistance Surveillance 1999–2002. Geneva, World Health Organization; 2004.
9. World Health Organization (WHO). Global tuberculosis control: surveillance, planning, financing. WHO report 2006. Geneva, World Health Organization (WHO/HTM/TB/2006.362).
10. Graham SM, Gie RP, Schaaf HS, Coulter JB, Espinal MA, Beyers N. Childhood tuberculosis: clinical research needs. *Int J Tuberc Lung Dis* 2004; **8**: 648–57.
11. Hesselning AC, Schaaf HS, Hanekom WA, Beyers N, Cotton MF, Gie RP et al. Danish bacille Calmette–Guerin vaccine-induced disease in human immunodeficiency virus-infected children. *Clin Infect Dis* 2003; **37**: 1226–33.
12. Siberry GK, Tessema S. Immune reconstitution syndrome precipitated by bacille Calmette Guerin after initiation of antiretroviral therapy. *Pediatr Infect Dis J* 2006; **25**: 648–9.
13. Puthanakit T, Oberdorfer P, Ukarapol N, Akarathum N, Punjaisee S, Sirisanthana T et al. Immune reconstitution syndrome from nontuberculous mycobacterial infection after initiation of antiretroviral therapy in children with HIV infection. *Pediatr Infect Dis J* 2006; **25**: 645–8.
14. Bastian I, Colebunder SR. Treatment and prevention multidrug-resistant tuberculosis. *Drugs* 1999; **58**: 633–61.
15. Schaaf UB. Fluoroquinolone antibiotics in infants and children. *Infect Dis Clin North Am* 2005; **19**: 617–28.
16. Burkhardt JE, Walterspiel JN, Schaaf UB. Quinolone arthropathy in animal versus children. *Clin Infect Dis* 1997; **25**: 1196–1204.
17. Graham SM, Gie RP, Schaaf HS, Coulter JB, Espinal MA, Beyers N. Childhood tuberculosis: clinical research needs. *Int J Tuberc Lung Dis* 2004; **8**: 648–57.
18. Pavlopoulou ID, Theodoridou M, Daikos GL, Lazopoulou DK, Koudounnakis E, Papadopoulos L et al. Drug-resistant tuberculous mastoiditis in 2 children. *Scand J Infect Dis* 2000; **32**: 436–8.
19. Lindquist SW, Steinmetz BA, Starke JR. Multidrug-resistant tuberculosis of the first cervical vertebra in an immunocompetent adolescent. *Pediatr Infect Dis J* 1997; **16**: 333–5.
20. Mehta JB, Mejia E, Gallemore GH, Ramsey GF. Drug-resistant tuberculosis of the brain in a two-year-old child. *Tenn Med* 1998; **91**: 285–7.
21. Drobac PC, Mukherjee JS, Joseph JK, Mitnick C, Furin JJ, del Castillo H et al. Community-based therapy for children with multidrug-resistant tuberculosis. *Pediatrics* 2006; **117**: 2022–99.
22. Curtis AB, Ridzon R, Vogel R, McDonough S, Hargreaves J, Ferry J et al. Extensive transmission of mycobacterium tuberculosis from a child. *N Engl J Med* 1999; **341**: 1491–5.
23. Stop TB Partnership and World Health Organization. Global Plan to Stop TB 2006–15. Geneva, World Health Organization, 2006. WHO/HTM/STB/2006.35.
24. World Health Organization. A research agenda for childhood tuberculosis. Geneva, World Health Organization, 2007. WHO/HTM/TB/2007.381. Accessed September 3, 2007 at <http://www.who.int/tb/publications/2007/en/index.html>