

A Caribbean Perspective on Barrett's Oesophagus

NP Williams¹

ABSTRACT

The aim of this study is to evaluate the prevalence of Barrett's oesophagus at the University Hospital of the West Indies which serves a population predominantly of African descent. In order to maximize accession of all cases in this preliminary study, the broad definition of columnar metaplasia of the lower oesophagus was utilized. Nevertheless, of 18 cases identified in the 21-year period, 14/17 cases (82%) available for review had specialized columnar epithelium diagnostic of Barrett's oesophagus. There was male predominance 5:1, the mean age was 53.8 years and there were two associated adenocarcinomas. These data confirm the occurrence but low prevalence of Barrett's oesophagus in this population but with a disease pattern that is consistent with that reported in other populations, warranting systematic evaluation of the gastro-oesophageal junction even in a Caribbean population.

Una Perspectiva Caribeña Sobre el Esófago de Barrett

NP Williams¹

RESUMEN

El objetivo de este estudio es evaluar la prevalencia del esófago de Barrett en el Hospital Universitario de West Indies – institución que presta servicio a una población predominantemente de descendencia africana. Con el objeto de maximizar el acceso de todos los casos a este estudio preliminar, se utilizó la definición amplia de metaplasia columnar del esófago inferior. Sin embargo, de 18 casos identificados en un período de 21 años, 14/17 casos (82%) disponibles para examen presentaban diagnóstico de epitelio columnar especializado de esófago de Barrett. Hubo predominio masculino 5:1, la edad media fue de 53.8 años, y hubo dos adenocarcinomas asociados. Estos datos confirman la incidencia, pero a la vez la baja prevalencia del esófago de Barrett en esta población, aunque con un patrón de enfermedad consistente con el que se reporta para otras poblaciones, justificando la evaluación sistemática de la unión gastroesofágica incluso en una población caribeña.

West Indian Med J 2006; 55 (3): 1

INTRODUCTION

Since its description in the early 1900s (1), the origin, significance and histologic characterization of Barrett's oesophagus have been controversial and problematic. Norman Barrett having first described it in association with peptic ulceration and oesophagitis (2), later mistakenly proposed that the abnormality resulted from "failure of the embryonic lining of the gullet to achieve normal maturity" (3). This columnar lining of the distal oesophagus is now recognized as a metaplastic change acquired with increasing age in some patients in response to gastric acid reflux (GERD) and possibly duodenal reflux (1, 4, 5). The significance and importance of this

metaplastic change lies firstly in the potential development of adenocarcinoma through progressive dysplasia (6) and secondly in the escalating incidence rates of adenocarcinoma of the lower oesophagus, which outstrips that of any other carcinoma (7).

What has remained uncontroversial is the observation that Barrett's oesophagus occurs primarily in men and is uncommon in Africa and persons of African descent in North America (8) and Africa (9) resulting in an equally low prevalence of adenocarcinoma of the lower oesophagus in this population in whom oesophageal carcinoma, despite recent increase in incidence (10) remains predominantly of squamous cell origin. While the same situation may be expected for persons of African descent in the Caribbean, no data are available to support this conclusion. Nevertheless, cancer incidence rates for the oesophagus reported from the Jamaica Cancer Registry are low, representing 2.3/100 000 in men and 1.4/100 000 in women (11) and have declined over the

From: Department of Pathology¹, The University of the West Indies, Kingston 7, Jamaica, West Indies.

Correspondence: Dr NP Williams, Department of Pathology, The University of the West Indies, Kingston 7. Fax: (876) 977-1811, e-mail nadia.williams@uwimona.edu.jm.

last 30 years (12). Reports from other Caribbean territories are also low (13). These data, however, do not separate the carcinomas into histological subtypes. In order to assess the prevalence of Barrett's oesophagus in this population, the files of the Department of Pathology at the University of the West Indies (UWI) were retrospectively reviewed for all possible cases of Barrett's oesophagus at the institution. This paper is the first documentation of Barrett's oesophagus in this population and discusses some of the possible explanations for the racial differences.

MATERIALS AND METHODS

The University Hospital of the West Indies (UHWI) is a tertiary referral centre that serves a population predominantly of African descent. The files of the Department of Pathology were retrospectively reviewed for all possible cases of Barrett's Oesophagus. As there is no specific code in the systematized nomenclature of pathology (SNOP) for Barrett's metaplasia SNOP codes 7500 – metaplasia, 7530 – glandular metaplasia, 7532 – intestinal metaplasia and 7600 – dysplasia were searched. Cases with dysplasia related to squamous epithelium were excluded. Cases included both biopsy and resected specimens. Where available, original or re-cut histological slides stained with H/E and Alcian blue/periodic acid Schiff (AB/PAS) were reviewed. The broad definition

of Barrett's oesophagus as replacement of the squamous epithelium by columnar epithelium resembling that in the stomach and intestine was used (4) and was sub-classified into specialized columnar, with goblet cells, junctional, resembling gastric cardia, and fundic, resembling atrophic gastric fundic mucosa (14). AB/PAS stain was performed on cases with junctional type mucosa only when vacuolated cells mimicked goblet cells (15). Presence and degree of dysplasia, presence and degree of accompanying inflammation and presence of adenocarcinoma were noted. A three-tiered modification of the grading system of dysplasia, consisting of no dysplasia, low-grade dysplasia (LGD) and high-grade dysplasia as recommended by Sampliner (15) was utilized. Demographic data, clinical data and endoscopic and radiographic features were evaluated.

RESULT

Between 1983 and 2003, 19 possible cases of Barrett's oesophagus were diagnosed with columnar metaplasia or dysplasia in glandular epithelium of the oesophagus. No cases were indexed prior to 1983. Slides were available from 1983 for all but the first case. On review, one case was excluded from analysis as the biopsy was superficial and represented by strips of foveolar epithelium only. The remaining 18 cases are summarized in Table 1 and consisted of 15 men and 3

Table 1: Clinicopathological data of Barrett's oesophagus

Case #	Age	Gender	Presentation	Clinical diagnosis	Endoscopy	Epithelial type	Dysplasia	Cancer
1	30	F	Symptomatic reflux, dyspepsia, Ba Meal neg	reflux oesophagitis				
2	82	M	Dysphagia x 6/52	Ca oesophagus	Polypoid mass distal 1cm oesophagus		Adenomatous (Papillary adenoma)	N
3	67	M	Upper abdom pain x 8yrs	Hiatus hernia; duodenal polyp		S/J	LGD	N
4	11	M	Reflux since birth	Long stricture on Ba swallow (oesophagectomy spec.)		J	N	N
5	58	F	Dysphagia x 1yr	oesophagitis	Distal oesophagitis; hiatus hernia	S	N	N
6	48	M	Dyspepsia and longstanding GERD; filling defect middle 1/3 on X-ray	Ca oesophagus	tumour beginning at 35cm	S/J	N	N
7	64	M	Upper GI bleed x1/52	Gastric ulcer	Hiatus hernia + 2 sessile polyps	S/J	N	N
8	60	M	Pain low sternal area; dysphagia; wgt loss x 4/52	Ca oesophagus/ cardia	Narrowed distal oesophagus + friable tumour	J	N	N
9	33	M	Dysphagia; vomiting; wgt loss x 5/12	?Leiomyomata ?Ca distal oesophagus	Large polypoid tumour, distal oesophagus with obstruction	S	Adenomatous + LGD ?HGD	N
10	45	M	Longstanding GERD	Barrett's oesophagitis	Grade 2 oesophagitis and features suggestive of Barrett's	J	N	N
11	55	M	Reflux x 10yrs	Oesophagitis ?Barrett's	Hiatus hernia + distal oesophagitis	S/J	N	N
12	43	M	Chronic GERD; long term PPI	Barrett's oesophagitis	Short segment Barrett's	S/J/F	N	N
13	72	M	Dysphagia x months	?Ca distal oesophagus	Stenosis distal oesophagus, area friable and oedematous	S	N	N

14	59	M	Chronic reflux; full dose PPI (pantecta 40mg daily)	Healed reflux oesophagitis R/O Barrett's	Irregular GEJ + gastric mucosa several cm up tubular oesophagus	1cm below Z-line – S/J	N	N
15	41	M	Reflux; dysphagia on PPI (ogastro & lansoprazole)	Chronic reflux R/O Barrett's	Z-line several cm up tubular oesophagus	S	N	Y
16	40	F	Abdom pain ?reflux H/O Barrett's and Stomach infection	R/O Barrett's; R/O HP	No ulceration or inflammation; Z-line up tubular oesophagus by 1–2cm	S/J/F	N	N
17	50	M	Abdom pain relieved by Nexium	?short segment Barrett's	Suggestive of short segment Barrett's	Z-line - J; 1cm below – J/F 2cm below – S/J/F	N N N	N N N
18	67	M	Longstanding hiatus hernia; endoscopic Dx Barrett's and Bx Dx of adenoca (Alternate Rx-antioxidants & vits)	Barrett's with dysplasia	Definite Barrett's 3cm above GEJ; hiatus hernia; no inflammation	Irregular area 2 cm above – S/J 1 cm above – S At Z-line – S	N N N LGD	Y N N N

Abdom = abdominal; adenoca = adenocarcinoma; Ba = barium; Bx = biopsy; Ca = carcinoma; Dx = diagnosis; epithelial types F = fundic, J = junctional, S = specialized; GEJ = gastro-oesophageal junction; GERD = gastro-oesophageal reflux disease; HGD = high grade dysplasia; HP = *Helicobacter pylori*; H/O = history of; LGD = low grade dysplasia; mths = months; Neg = negative; PPI = proton pump inhibitor; Rx = therapy; Spec = specimen; vits = vitamins; wgt = weight.

women (ratio 5:1). There was only one resection specimen from an 11-year-old boy with a history of gastro-oesophageal reflux since birth and a long stricture on barium swallow. Figure 1 shows the age distribution. The age range exclud-

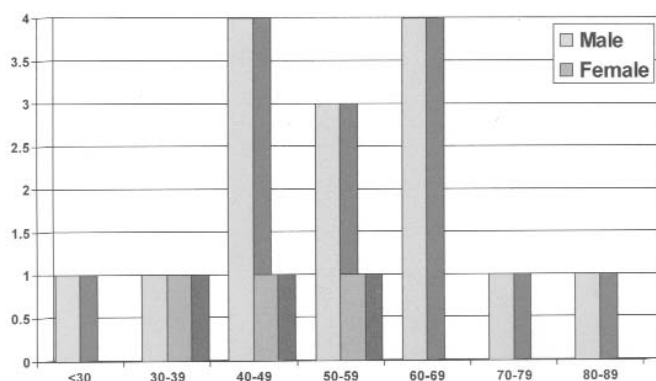


Fig 1: Age distribution of Barrett's Oesophagus

ing the child was 30–82 years with a mean of 53.8 years. Five cases were from the Cayman Islands where the resident population is more cosmopolitan but only one patient (Case 18) was Caucasian.

Figure 2 shows the histological and histochemical characteristics of Barrett's oesophagus and associated adenocarcinoma. On review, specialized columnar epithelium, which is considered specific for Barrett's oesophagus (4, 6) was present in 14/17. Three cases had junctional epithelium

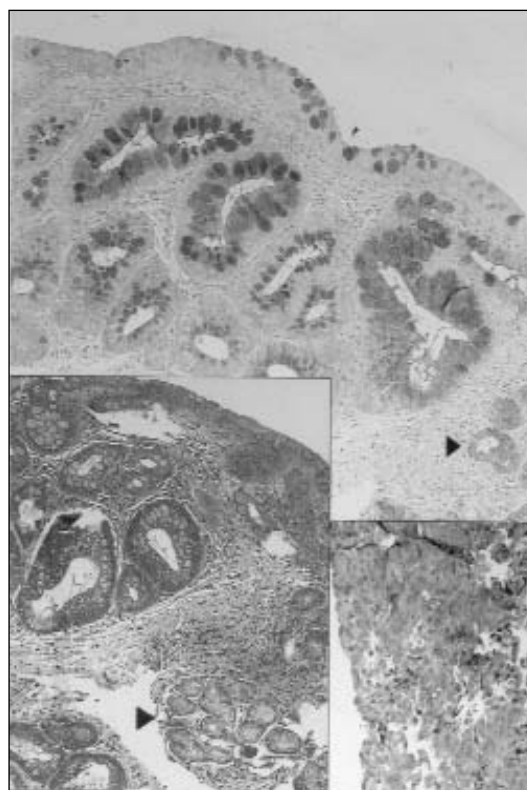


Fig 2: Metaplastic specialized columnar epithelium with goblet cells in Barrett's oesophagus stained with Alcian Blue/PAS while fundic type mucosa (<) remains unstained. Inset Left: (H/E); Inset Right: Moderately differentiated adenocarcinoma.

alone while fundic type mucosa was found in combination with specialized columnar epithelium in three cases. There were two associated carcinomas and four cases with dysplasia – two LGD and two villiform or papillary HGD.

DISCUSSION

Although the definition of Barrett's oesophagus has evolved over the years and current guidelines recommend the histological confirmation of intestinal metaplasia in any length of the tubular oesophagus for the diagnosis (6, 15), the wider definition of columnar metaplasia as characterized by Paull *et al* (14) was used in this report in an attempt to maximize accession. In addition, requisite in the current guidelines is adequate and systematic sampling of abnormal appearing mucosa at endoscopy whereas for the most part, these cases reflected a more random and somewhat limited biopsy protocol. It is also recognized that representative biopsies are often difficult due to the inherent irregularity of the squamocolumnar junction (4) and furthermore inconsistencies are well recognized in the endoscopic recognition and histologic diagnosis of Barrett's oesophagus. Despite this, Goldblum has suggested that if the endoscopic appearances are suggestive of Barrett's oesophagus, the absence of specialized columnar epithelium may simply reflect sampling error and the diagnosis may still be strongly suggested (16). It is significant that 14/17 (82%) of the cases in this study had specialized columnar epithelium alone or in conjunction with the other types, confirming the occurrence of Barrett's oesophagus in this population. High-grade dysplasia, which is often associated with a papillary mass was evident in this study. Mucosal irregularity has also been found to be predictive of the presence of carcinoma (15) and carcinoma was present in one patient (Case 18) in whom mucosal irregularity was noted.

Explanations for the racial discordance presume inherent genetic differences or differences in the prevalence of the various associated factors (4). Since the original description, gastro-oesophageal reflux and hiatus hernia have long been recognized as significant associated aetiological factors (1). Spechler *et al* have found statistically significant racial differences in frequency and complications of GERD (8) among White, Black and Asian patients. Simko and Ayoade however, found that although hiatus hernias were less common and smaller in African-Americans as compared to Caucasians and Hispanics, large hiatal hernias did occur and therefore they surmised that it was unlikely that distal oesophageal competence could explain the rarity of Barrett's oesophagus in Blacks (17). Segal proposed that the critical factor preventing GERD in black Africans was *Helicobacter pylori* (HP) infection, which was acquired in childhood and was probably protective of the oesophagus (9). This has been supported by Wang *et al* who found that HP infection and Barrett's oesophagus are inversely related, suggesting a protective role of HP against its development (18). *Helicobacter pylori* infection is common in the Caribbean with reported

rates exceeding 50% (19, 20, 21) and seroprevalence rates approaching 70% (22).

Obesity and increased body mass index (BMI) are implicated in the genesis of GERD but their role in the development of BE is controversial. Chang *et al* found no statistically significant relationship between Barrett's oesophagus and BMI in a study of 137 patients with BE and 138 age and sex-matched controls (23). Epidemiologic data from Jamaica showed that 26.1% of males and 32.5% of females were overweight while 8.5% of males and 33.9% of females were obese when BMI was classified as normal (< 25), overweight (25 – < 30), and obese (≥ 30) (24). Zohoori *et al* further reported that over the age of 50 years, which is the population at risk for Barrett's oesophagus, there was a decrease in the prevalence of overweight with an increased prevalence of underweight (25). Therefore, increased BMI does not seem to be a significant risk factor for the development of Barrett's oesophagus in Caribbean people. Alcohol intake and cigarette smoking, which are significantly associated with squamous cell carcinoma, are also apparently not major risk factors. In this study, the male predominance is consistent but the mean age at diagnosis of 53.8 years is a decade younger than that reported by Cameron and Lomboy (5). The finding of two cases of adenocarcinoma representing 11% prevalence is also consistent with previous reports (4).

These findings confirm that Barrett's oesophagus occurs in Caribbean populations, albeit infrequently, as was expected for a population predominantly of African descent but the pattern of disease and associated development of adenocarcinoma is characteristic. Systematic evaluation of the gastro-oesophageal junction is therefore warranted even in Caribbean nationals. The reasons for the racial differences remain moot but appear to be more related to varying prevalence of associated aetiological factors than to genetic differences.

ACKNOWLEDGEMENTS

The author is grateful for assistance with data management from Mr Laurel Choy, histochemical stains from Ms Gillian Mignott and photography from Mr Conrad Raymond.

REFERENCES

1. Spechler SJ, Goyal RK. The columnar-lined esophagus, intestinal metaplasia and Norman Barrett. *Gastroenterology* 1996; **110**: 614–21.
2. Barrett NR. Chronic peptic ulcer of the oesophagus and 'oesophagitis.' *Br J Surg* 1950; **38**: 175–82.
3. Barrett NR. The lower oesophagus lined by columnar epithelium. *Surgery* 1957; **41**: 881–94.
4. Spechler SJ and Goyal RK. Barrett's esophagus. *N Engl J Med* 1986; **315**: 362–71.
5. Cameron AJ and Lomboy CT. Barrett's esophagus: Age, prevalence, and extent of columnar epithelium. *Gastroenterology* 1992; **103**: 1241–5.
6. Haggitt RC. Barrett's esophagus, dysplasia, and adenocarcinoma. *Hum Pathol* 1994; **25**: 982–93.
7. Devesa SS, Blot WJ, Fraumeni JF. Changing patterns in the incidence of esophageal and gastric carcinoma in the United States. *Cancer* 1998; **83**: 2049–53.

8. Spechler SJ, Jain SK, Tendler DA, Parker RA. Racial differences in the frequency of symptoms and complications of gastro-oesophageal reflux disease. *Aliment Pharmacol Ther* 2002; **16**: 1795–800.
9. Segal I. The gastro-oesophageal reflux disease complex in sub-Saharan Africa. *Eur J Cancer Prev* 2001; **10**: 209–12.
10. Firoozi B, Vega KJ, Holland BK, Koliver MG, Trotman BW. Epidemiologic pattern of esophageal cancer at an inner-city university hospital. *J Assoc Acad Minor Phys* 1999; **10**: 44–7.
11. Hanchard B, Blake G, Wolff C, Samuels E, Waugh N, Simpson D et al. Age-specific incidence of cancer in Kingston and St Andrew, Jamaica, 1993–1997. *West Indian Med J* 2001; **50**: 123–9.
12. Brooks SEH and Wolff C. 30-year cancer trends in Jamaica: Kingston and St Andrew (1958 – 1987). *West Indian Med J* 1991; **40**: 134–8.
13. Brooks SEH and Wolff C. Cancer in the Caribbean and Environs: A comparison of age-standardized rates for 9 population groups. *West Indian Med J* 1992; **41**: 103–10.
14. Paull A, Trier JS, Dalton MD, Camp RC, Loeb P, Goyal RK. The histologic spectrum of Barrett's esophagus. *N Engl J Med* 1976; **295**: 476–80.
15. Sampliner RE. Updated guidelines for the diagnosis, surveillance, and therapy of Barrett's esophagus. *Am J Gastroenterol* 2002; **97**: 1888–95.
16. Goldblum JR. Barrett's esophagus and Barrett's-related dysplasia. *Mod Pathol* 2003; **16**: 316–24.
17. Simko V, Ayoade F. Distal esophageal competence: Does it explain paucity of Barrett's and rarity of esophageal adenocarcinoma in African Americans (AA)? *Am J Gastroenterol* 2003; **98** (suppl): S41
18. Wang C, Yuan Y, Hunt R. *Helicobacter pylori* infection and Barrett's esophagus: A meta-analysis. *Am J Gastroenterol* 2003; **98**: S15.
19. Lee MG, Arthurs M, Terry SI, Donaldson E, Scott P, Bennett F et al. *Helicobacter pylori* in patients undergoing upper endoscopy in Jamaica. *West Indian Med J* 1994; **43**: 84–6.
20. Edwards CN, Douglin CP, Prussia PR, Garrigues SA, Levett PN. Epidemiology of *Helicobacter pylori* infection in Barbados. *West Indian Med J* 1997; **46**: 3–7.
21. Weill FX, Margeridon S, Broutet N, Le Hello S, Neyret C, Megraud F. Seroepidemiology of *Helicobacter pylori* infection in Guadeloupe. *Trans R Soc Trop Med Hyg* 2002; **96**: 517–9.
22. Lindo JF, Lyn-Sue AE, Palmer CJ, Lee MG, Vogel P, Robinson RD. Seroepidemiology of *Helicobacter pylori* infection in a Jamaican community. *Trop Med Int Health* 1999; **4**: 862–6.
23. Chang GL, Victor JT, Mahdavian M. A retrospective study assessing Barrett's esophagus and its correlation with Body Mass Index [Abstract]. *Am J Gastroenterol* 2003; **98** (suppl): S10.
24. Mendez MA, Cooper R, Wilks R, Luke A, Forrester T. Income, education, and blood pressure in adults in Jamaica, a middle-income developing country. *Int J Epidemiol* 2003; **32**: 400–8.
25. Zohoori N, Jackson M, Wilks R, Walker S, Forrester TE. Nutritional status of older adults in Urban Jamaica. *West Indian Med J* 2003; **52**: 111–7.